

REVIEW ARTICLE

Acute Acalculous Cholecystitis in Critically ill Patients: Risk Factors, Diagnosis and Treatment Strategies

Senival Alves de Oliveira Júnior, Thiago Emanuel Vêras Lemos, Arnaldo Costa de Medeiros Junior, Artur Dantas Freire, César de Carvalho Garcia, Rielly de Sousa e Silva, Amália Cinthia Meneses Rêgo, Irami Araújo Filho

Potiguar University, Laureate International Universitie, Natal, Rio Grande do Norte, Brazil

ABSTRACT

Background Acute acalculous cholecystitis is a condition that usually occurs due to severe clinical status, it is relatively rare and hard to diagnose. A pathology that presents multifactorial etiology, it has been reported in the postoperative period, in burn patients and in association with sepsis, diabetes mellitus, vasculitis and parenteral nutrition. This article is an updated bibliographical review concerning the etiology, diagnosis and therapeutic management of acute acalculous cholecystitis. **Method** Articles were selected following research in the PubMed, Scielo, Scopus and Web of Science databases using the keywords acute cholecystitis, gallbladder diseases, acalculous cholecystitis, surgical intensive care, patient care, critical care. **Results** The mortality rate of patients with acute acalculous cholecystitis remains high and is mainly due to the serious underlying medical conditions and rapid progression of the disease to gangrene and perforation. The definitive therapy is a cholecystectomy and the draining of abscesses that occur during the clinical course of the disease.

INTRODUCTION

Acute cholecystitis is a pathology in which the gallbladder wall becomes inflamed [1]. Gallstones are the primary triggering factor in 90% of the causes of cholecystitis, they are present in more than 10% of the population and their presence increases with age [1]. The main factors for the formation of gallstones are diabetes mellitus, estrogen, pregnancy, cirrhosis, obesity and hemolytic disease [1]. However, in approximately 2 to 15% of cases, acute cholecystitis can occur without the presence of gallstones, and these are named acute acalculous cholecystitis (AAC), a condition that is diagnosed with increasing frequency in critical patients and is reported worldwide [1, 2, 3, 4, 5].

AAC is predominant in male patients aged 50 years old and over (80% of cases) [2, 3, 6]. It is reported in the postoperative period of non-traumatic surgery, in burn patients and in association with sepsis, diabetes mellitus, vasculitis (including polyarteritis nodosa) and prolonged use of parenteral nutrition [7]. Untreated, its short-term

mortality can reach 35% [8], while long-term mortality rate can reach 59% [9].

There are reports of its emergence in previously healthy children [10, 11, 12, 13] and in children with infection or trauma, AAC corresponds to 30 to 70% of acute cholecystitis [14].

The incidence of AAC following open abdominal aortic reconstruction varies between 0.7% and 0.9% [14, 15]; moreover, this condition has been reported as a complication in endovascular aortic repair [16].

After heart surgery, the incidence of acute cholecystitis was low in medical reports of 31,710 patients, with a mortality rate of approximately 45% [6]. Although it is a rare event following heart surgery, patients submitted to cardiac valve replacement, with or without revascularization surgery, are at potential risk due to associated cardiomyopathy [17].

Approximately eighty percent (80%) of patients diagnosed with AAC following surgery in the absence of trauma are men [6].

AAC usually occurs after severe clinical disease or trauma, such as extensive burns, polytrauma, major surgery, end stage renal disease (ESRD), leukemia and severe infection [14]. However, the development of AAC is not limited to surgical patients, traumatic wounds or critical illness [18, 19]. Patients with diabetes due to cholesterol and post-hemorrhagic shock resuscitation have been diagnosed with AAC [20, 21]. Besides these conditions, ESRD is a predisposing factor, because

Received July 26th, 2016 - Accepted August 28th, 2016
Keywords Acalculous Cholecystitis; Cholecystitis, Acute; Critical Care; Gallbladder Diseases; Patient Care
Abbreviations AAC acute acalculous cholecystitis; ESRD end stage renal disease
Correspondence Irami Araújo Filho
Potiguar University
Laureate International Universitie
Natal, Rio Grande do Norte, Brazil
Phone + 55 (84) 98876-0206 / 3342-5027
Fax + 55 (84) 3342-5079
E-mail irami.filho@uol.com.br / irami.filho@gmail.com

diabetes mellitus and atherosclerosis are common in the final of the disease, which often evolves with low-flow hemodialysis [22]. Hemorrhagic AAC has been reported in patients with ESRD, especially when related to any uremic thrombocytopenia or frequent exposure to uremic heparinoids [23].

Research indicates that the development of a secondary infection of the gallbladder: can involve disseminated candidiasis or leptospirosis; and occurs during systemic sepsis, in patients with chronic biliary tract diseases, such as typhoid fever and non-typhoid *Salmonella* typhoid; and during diarrheal diseases, such as cholera or *Campylobacter* enteritis and tuberculosis. Cases of AAC have also been reported with malaria, brucellosis, *Coxiella burnetii* and dengue. Several viral pathogens are associated with AAC, including hepatitis A, hepatitis B and Epstein-Barr virus [24, 25, 26, 27, 28, 29, 30].

It is important to emphasize that extrahepatic biliary obstruction can lead to this pathology in two distinct forms, and can involve infectious or non-infectious causes. Infective obstructive causes include ascariasis and cysts of *Echinococcus* eggs. The non-infectious etiology is intrinsically linked to hemophilia, bile duct cysts and ampullary stenosis [31, 32, 33, 34, 35].

In addition, acalculous gallbladder disease occurs in AIDS patients, and can take one of two forms. The first is cholestasis, which may be impossible to distinguish from bacterial cholangitis in a patient with acute jaundice or typical AAC, although this association is increasingly rare due to the progress of antiretroviral therapy. However, in this group of patients, there are reports of associations with human cytomegalovirus and infections due to *Cryptosporidium* and microsporidia [36, 37, 38, 39].

Dehydration is an important precipitating factor, as are acute bacterial and viral diseases, such as hepatitis and infections of the upper respiratory tract. Portal lymphadenitis with extrinsic cystic duct obstruction may be associated with the etiology in the presence of viral infections [40, 41, 42].

A relationship between AAC and Kawasaki disease has been reported and although the pathophysiology is unknown, proposed mechanisms include adenopathies of the cystic duct leading to obstruction, vasculitis or perivasculitis of the gallbladder wall, and infiltration by inflammatory cells [43, 44, 45].

Parenteral nutrition (PN) can also provoke AAC. The loss of enteric stimulation occurring during PN impairs gallbladder motor function, favoring the development of a sluggish gallbladder. This explains the frequent association between PN and gallbladder dysfunction, including abnormal gallbladder dilatation and the development of AAC, biliary sludge and gallstones [46].

Acute acalculous cholecystitis is very rare as a complication of Systemic lupus erythematosus (SLE). Despite the rarity, we should not forget that acute

acalculous cholecystitis can be the initial manifestation of SLE [47, 48, 49, 50, 51, 52]. Considering the few cases in literature, conservative treatment with high-dose corticosteroid should be attempted [53, 54]. Although, cholecystectomy has been the treatment of choice in those patients [47, 48].

MATERIALS AND METHODS

This work consists of a literature review in the databases PubMed, Scielo, Scopus and Web of Science. Data was collected on case reports, cohort studies and literary reviews, using the keywords "*acute cholecystitis, gallbladder diseases, acalculous cholecystitis, surgical intensive care, patient care, critical care*". The method used the following guiding question: "*what are the main results and scientific evidence identified in national and international bibliographic production, over the last thirty years, concerning the diagnosis and therapeutic management of acute acalculous cholecystitis?*".

During an initial survey, we identified 105 articles, which were evaluated by all the authors, according to the following inclusion criteria: articles published in Portuguese, English or Spanish that presented combinations of the selected keywords in the title or abstract, published between January 1985 and December 2015. After this initial selection, all the abstracts were read and repeated articles from different databases and those that did not cover the theme proposed were excluded. Although articles were selected based on effective updates in treatment, therapeutic failure was not used as a criterion for exclusion. The particularities of the disease presentation in each case were considered, according to the methodology of each study. The final material featured 93 scientific articles.

RESULTS

Etiology

Escherichia coli and other gram-negative enteric bacteria are most frequently isolated microorganisms [9], but numerous agents have been related to this pathology, including dengue viruses, cytomegalovirus, varicella zoster, Epstein-Barr virus, hepatitis A virus, *Leptospira* spp, *Salmonella* spp, *Vibrio cholerae*, *Coxiella Burnetti*, *Plasmodium falciparum*, *Cryptosporidium* and *Candida* spp [2, 55].

Individuals with HIV that present opportunistic infections, such as cytomegalovirus, *Cryptosporidium*, *Mycobacterium tuberculosis*, *M. avium intracellulare* or fungal infections, are described as at higher risk of developing AAC [56].

There are reports of rare cases caused by *Lactococcus garvieae*, which is known as a pathogenic agent in fish [56], and a rare complication in cases of *Salmonella* infection, with a maximum rate of 0.6% isolation. Ischemia of the gallbladder and cystic artery obstruction constitute the basis of the development of the latter pathology [57, 58].

Pathophysiology

The pathogenesis of AAC is not yet well defined, and its exact mechanism remains unknown [59]. Studies show that several factors, including ischemia, infection and biliary changes are involved. Thus, AAC shows multifactorial etiology.

Patients with visceral atherosclerosis may be at increased risk of AAC due to impaired mucosal resistance [59]. AAC also occurs under conditions of sepsis and in immunosuppressed patients [3]. Yet another established risk factor is diabetes mellitus [60]. It is known that trauma, burns, major surgery particularly involving the heart valves, prolonged parenteral nutrition [61], vasculitis (including polyarteritis nodosa), use of opioids and the use of positive pressure ventilation can trigger the disease [1, 5, 7].

Disease etiology remains uncertain, but the current hypothesis is that the bile of patients with severe cholestasis, usually not fed enterally, provokes distention and increased tension inside the gallbladder wall, compromising the blood supply. In addition to the frequent occurrence of ischemia, the presence of bacterial proliferation and the activation of pro-inflammatory mediators can result in gangrene of the gallbladder [1, 7]. Another possibility is direct viral invasion of the gallbladder, as described by Mourani *et al.* [62] in their case of hepatitis A associated cholecystitis infection.

Given these findings, it is important to highlight the four factors that seem most closely related to the onset of AAC [63]: 1) biliary stasis – changes in the smooth muscle of the gallbladder and sphincter of Oddi dysfunction lead to biliary stasis through changes in bile composition and gallbladder injury [64]; 2) systemic inflammatory response – the response to systemic injury and subsequent release of inflammatory mediators, such as factor XII and platelet-activating factor induce an inflammatory process in the gall bladder; 3) visceral ischemia-reperfusion injury – a decrease in bile acid synthesis and secretion leads to gallbladder hypomotility, together with a reduction in blood pressure (similar to hypovolemic shock), an increase in intraluminal pressure of the gallbladder and decreased perfusion, resulting in ischemia; and 4) infectious diseases – tuberculosis should be included in any differential diagnosis, particularly in immunocompromised patients [65], while *Salmonella* is a likely infectious agent when diarrhea is present, since it can disseminate through the blood or lymph system even weeks after the initial infection. The remaining agents have been previously cited [60, 66]. It is worth highlighting that children can also be affected by AAC following viral infection [1, 67].

The evolution of AAC during the course of acute infection by Epstein-Barr virus (EBV) is not well understood. However, it is believed that direct EBV invasion and/or irritation of the gallbladder due to bile stasis, are the main factors involved. Of interest, AAC seem to occur more often in young women during acute infection by EBV [68]. It is

worth emphasizing that the presence of upper respiratory system symptoms and hematological findings compatible with viral infection can be useful for diagnosing EBV-related AAC [69, 70]. However, the presence of clinical data, laboratory and ultrasound findings compatible with AAC can result in diagnostic dilemmas and unnecessary therapeutic processes [69, 70, 71].

Clinical Status

Pain in the right hypochondrium, radiating to the scapula and epigastric region, characterize the onset of the condition. Fever, nausea and vomiting may be present in up to 70% of patients [1].

The formation of abscesses, poor perfusion or gangrene in the gallbladder should raise suspicions in the presence of high fever, chills, leukocytosis and decreased peristalsis [1]. Since many of these symptoms are frequently observed in patients with severe conditions, who require sedation, the clinical examination can be impaired, thus impeding prompt diagnosis [1].

In up to 20% of cases, a palpable mass is observed, representing the swollen gallbladder. Murphy's sign may also be present, demonstrating visceral-parietal compromise of the peritoneum [1].

Other findings, such as fever, nausea, vomiting, diarrhea, dyspepsia, fatigue, altered mental status and jaundice may be present, but they are very nonspecific symptoms [55, 63].

Diagnosis

Since it is an uncommon disease, a diagnosis of AAC is often delayed, a factor that has an important impact on its mortality (10-50%) compared with acute calculous cholecystitis (approximately 1%) [72].

The clinical and radiological manifestations of AAC are the same as those of acute calculous cholecystitis, except for a lack of evidence of gallstones. Thus, the diagnosis should always be considered in critical hospitalized or chronically ill patients, when they present abdominal pain, fever and unexplained leukocytosis and sepsis [5, 73].

The degree of suspicion is generally high, because its diagnosis is difficult and is usually confirmed following clinical examination, laboratorial results and radiological and/or surgical findings [55, 63].

The hemogram may show leukocytosis with left shift, while other exams show increases in transaminases, alkaline phosphatase, bilirubin and amylase [1].

Currently, there is some controversy concerning the optimal image mode and the first mode that should be used to achieve a diagnosis of AAC [74]. It is important to note that no radiological mode alone is sensitive or specific enough to confirm a diagnosis [74].

Ultrasound is the imaging exam of choice when initiating an investigation, due to its high sensitivity for gallstones and for observing abnormal wall thickening

(> 3 mm) [1, 74]. In addition, Murphy’s sign is evident in ultrasound, revealing a tense and swollen gallbladder, pericholecystic fluid and the absence of gallstones. Its sensitivity and specificity can vary from 30% to 100% [2]. Furthermore, an ultrasound can reveal the absence of biliary sludge, gallbladder distention greater than 0.5 cm, gallbladder striation, mucosal peeling, emphysematous cholecystitis and gallbladder perforation [71, 74].

Therefore, to define strong suspicion of AAC by ultrasound, two major criteria or one major and two minor criteria are required (Table 1) [74, 75, 76, 77, 78, 79, 80].

Although abdominal radiography is not used to diagnose acalculous cholecystitis, it is useful to exclude gallbladder perforation and investigate evidence of alternate diagnoses, such as ischemic bowel or kidney stones [71]. The presence of two or more of the following criteria favor a diagnosis of AAC: positive Murphy’s sign, gallbladder wall thickening >3 mm, gallbladder distension and the presence of perivesicular liquid in the absence of gallbladder stones [2, 52, 80].

Computed tomography (CT) and nuclear magnetic resonance imaging (MRI) can be used in cases where ultrasound is insufficient for diagnostic clarification [1, 74]. MRI is not a routine examination, since it shows no real advantages over other imaging methods [74]. The main findings when using MRI are thickening of the gallbladder wall, increased bile density, irregular mucosa, lumen distension, intramural gas, pericholecystic fluid accumulation and intraluminal bleeding [65, 74]. It should be emphasized that CT scans show greater sensitivity and specificity for diagnosing AAC than ultrasound [81] (Figure 1).

CT scans are also used in suspected cases of other intra-abdominal processes that are not been observed using other diagnostic methods [78].

Biliary scintigraphy can demonstrate the absence of gallbladder filling in AAC, and is the gold standard method for diagnosis [82]. Its specificity is reportedly as high as 100% [74, 82].

Diagnostic laparoscopy and laparotomy have been recommended by the Society of American Gastroenterological Association and Endoscopic Surgeons for critically ill patients, when a diagnosis of AAC is suspected and cannot be excluded by non-invasive methods [74].

Treatment

It is important to highlight that due to the serious clinical status of patients with AAC and its rapid evolution to gangrene and perforation, even with the establishment of prompt and adequate treatment, the mortality rate is around 30% [11, 63].

The preferred treatment for AAC is an emergency cholecystectomy, either by open or laparoscopic approach, since the disease has a high probability of catastrophic

progression [83, 84]. However, in cases where the etiology of AAC is *Salmonella enteritidis* infection, conservative management with antibiotics is the best therapeutic option in the absence of complications [84]. A 4 to 6-week course of broad-spectrum antibiotics is usually sufficient to resolve the symptoms. If the symptoms cease and the control ultrasound shows a non-dilated gallbladder with a thin wall, cholecystectomy is not required. Patients who are treated with a long course of broad-spectrum antibiotics often show good prognosis [58].

Conservative treatment is also recommended for patients with dengue, since they do not present diffuse peritonitis or perforation upon diagnosis. Patients submitted to cholecystectomy or percutaneous cholecystostomy can present bleeding that requires a transfusion and even prolonged hospitalization (4.1±1.6 days for conservative therapy vs. 16–18 days for those submitted to invasive therapy) [85].

If the patient is a candidate for surgery, laparoscopic cholecystectomy should be performed early, since this reduces the period of hospitalization and complication rates, while mortality appears to remain unaffected [5, 55]. Due to the incidence of necrosis and gangrene, cholecystectomy is preferable to cholecystostomy when there is no relationship between the symptoms and the ultrasound findings [63].

General care, such as hospitalization, fasting, hydration and electrolyte replacement are essential, as is analgesia for pain relief [1]; however, neither morphine nor its derivatives are recommended due to the risk of sphincter of Oddi spasms. The use of antibiotics is recommended, which should include gram-negative and anaerobic microorganisms; the well-documented involvement of *Escherichia coli* is worth highlighting again [1].

DISCUSSION

Half of patients with AAC may present additional complications at the time of diagnosis, such as gangrene, gallbladder perforation, empyema and emphysematous cholecystitis. These conditions are more common with AAC than acute calculous cholecystitis, and should always prompt suspicion of AAC. When undiagnosed, clinical deterioration is usually rapid and catastrophic [5, 55, 72].

Although numerous diagnosed patients are not in an ideal condition for surgery, a temporary percutaneous cholecystostomy is often performed. It is an invasive procedure, which involves gallbladder decompression and

Table 1. Ultrasound criteria for diagnosing acute acalculous cholecystitis.

Major Criteria
Gallbladder wall thickness ≥3.5 mm.
Pericholecystic fluid or subserosal edema - distention >5 cm in length, without associated ascites or hypoalbuminemia.
Intramural gas; emphysematous cholecystitis
Mucosal peeling
Minor Criteria
Biliary sludge
Hydrops - distension >8 cm in length or >5 cm in width, with clear liquid.

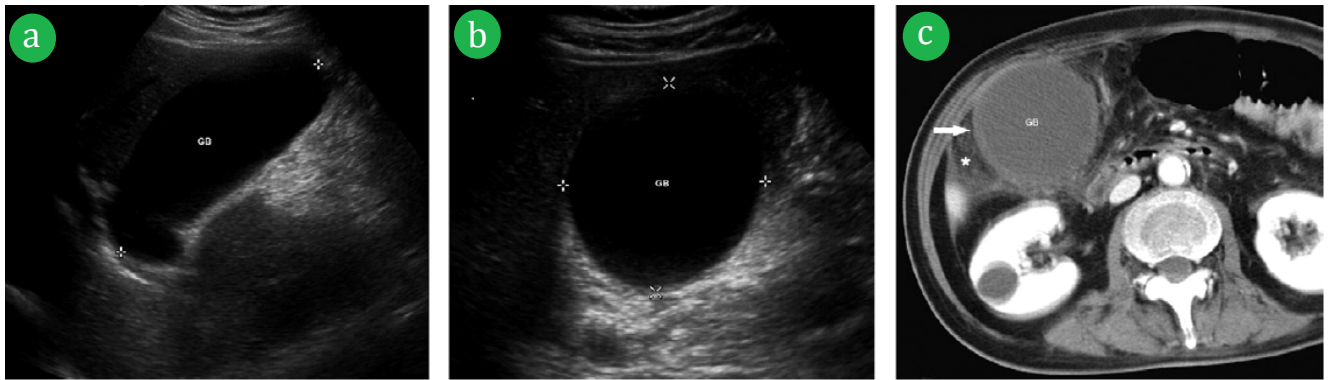


Figure 1. (a, b). Longitudinal and horizontal ultrasound of a 64-year-old man with positive Murphy's sign, showing hydrops. (c). CT scan 6 hours later showing thickened gallbladder wall (white arrow), hydrops and pericholecystic inflammation (asterisk).

the control of inflammation. The cholecystostomy tube remains in place until the patient is deemed clinically well enough to be submitted to a cholecystectomy, usually 6-8 weeks after recovery from acute cholecystitis [5, 11, 74].

The mortality rate of this procedure is less than 3% [78, 80]. Fully decompressing the inflamed gallbladder by percutaneous drainage can provide rapid improvement in symptoms. Recent studies report that more than 90% of patients show relief of symptoms after three days of draining [86, 87, 88, 89, 90, 91].

The main complications with this procedure are biliary tract rupture, pain at the puncture site, catheter hemorrhage or dislocation [2, 92] and the recurrence of the condition following the removal of the percutaneous drainage catheter in patients with AAC, 21.7 to 46.7% over a mean follow-up period of 12 to 37 months [93, 94, 95, 96].

COMMENTS

Regardless of the treatment chosen, the mortality rate of patients presenting acute acalculous cholecystitis remains high, and is mainly due to the serious underlying medical conditions and the rapid progression of the disease to gangrene and perforation.

Although it is a rare pathology that is difficult to identify, with a detailed initial assessment and complementary examinations, achieving a good diagnosis is possible.

The definitive therapeutic management involves cholecystectomy, with drainage of any associated abscesses, though cholecystostomy is often preferred due to its less invasive character.

The number of published works on this pathology limits our knowledge regarding acute acalculous cholecystitis and indicates that future research is required to improve current understanding of its pathophysiology, risk factors and treatment management, aimed at a clearer comprehension of the many aspects of this disease.

Conflicting Interest

The authors had no conflicts of interest

References

1. Maya MCA, Freitas RG, Pitombo MB, Ronay A. Colecistite aguda: diagnóstico e tratamento. *Revista Hospital Universitário Pedro Ernesto* 2009; 8:52-60.
2. Carvalho D, Azevedo C, Coelho R, Ferreira A, Figueiredo P, Santos L, Sarmiento A. Colecistite aguda alitiásica. *Acta Med Port* 2011; 24:631-634.
3. Kalliafas S, Ziegler DW, Flancbaum L, Choban PS. Acute acalculous cholecystitis: incidence, risk factors, diagnosis, and outcome. *Am Surg* 1998; 64:471-5. [PMID: 9585788]
4. Vakkala M, Laurila J, Saarnio JJ, Koivukangas V, Syrjälä H, Karttunen T, Soini Y, et al. Cellular turnover and expression of hypoxic-inducible factor in acute acalculous and calculous cholecystitis. *Critical Care* 2007; 11:R116. [PMID: 17974017]
5. Knab LM, Boller AM, Mahvi DM. Cholecystitis. *Surg Clin North Am* 2014; 94: 455-470. [PMID: 24679431]
6. Barie PS. Acalculous and postoperative cholecystitis. In: Barie PS, Shires GT, editors. *Surgical intensive care*. Boston: Little, Brown 1993; 837-57.
7. Aitken E, Lyon A, Felstenstein I. An unusual case of acalculous cholecystitis heralding presentation of acute mesenteric ischaemia with typical radiological findings. *Int J Surg Case Rep* 2012; 3:346-348. [PMID: 22580081]
8. Beckman I, Dash N, Sefczek RJ, Lupetin AR, Anderson JS, Diamond DL, Young JC. Ultrasonographic findings in acute acalculous cholecystitis. *Gastrointest Radiol* 1985; 10:387-389. [PMID: 3902551]
9. McGahan JP, Lindfors KK. Percutaneous cholecystostomy: an alternative to surgical cholecystostomy for acute cholecystitis? *Radiology* 1989; 173:481-485. [PMID: 2678261]
10. McNaughton C, Morrow S, Cico SJ. Acalculous cholecystitis in a healthy 4-year-old boy. *Am J Emerg Med* 2011; 29:962. [PMID: 20970290]
11. Huffman JL, Schenker S. Acute acalculous cholecystitis: a review. *Clin Gastroenterol Hepatol* 2010; 8:15-22. [PMID: 19747982]
12. Ganpathi IS, Diddapur RK, Eugene H, Karim M. Acute acalculous cholecystitis: challenging the myths. *HPB(Oxford)* 2007; 9:131-4. [PMID: 18333128]
13. Croteau D, Signer RD, Chaet MS. Acalculous cholecystitis in a two-year-old. *JSLS* 2001; 5:183-5. [PMID: 11394434]
14. Tsakayannis DE, kozakewich H, Lillehei CW. Acalculous cholecystitis in children. *J Pediatr Surg* 1996; 31:127-31. [PMID: 8632265]
15. Ouriel K, Green RM, Ricotta JJ, DeWeese JA, Adams JT. Acute acalculous cholecystitis complicating abdominal aortic aneurysm resection. *J Vasc Surg* 1984; 1:646-8. [PMID: 6502835]
16. Cadot H, Addis MD, Faries PL, Carroccio A, Burks JA Jr, Gravereaux EC, Morrissey NJ, et al. Abdominal aortic aneurysmorrhaphy and cholelithiasis in the era of endovascular surgery. *Am Surg* 2002; 68:839-43. [PMID: 12412707]

17. Leitman IM, Paull DE, Barie PS, Isom OW, Shires GT. Intraabdominal complications of cardiopulmonary bypass surgery. *Surg Gynecol Obstet* 1987; 165:251-4. [PMID: 3498228]
18. Papaioannou CC, Hunder GG, Lie JT. Vasculitis of the gallbladder in a 70 year old man with giant cell arteritis. *J Rheumatol* 1979; 6:71-5. [PMID: 439115]
19. Dessailoud R, Papo T, Vaneecloo S, Gamblin C, Vanhille P, Piette JC. Acalculous ischemic gallbladder necrosis in the catastrophic antiphospholipid syndrome. *Arthritis Rheum* 1998; 41:1318-20. [PMID: 9663491]
20. Moolenaar W, Lamers CB. Cholesterol crystal embolization to liver, gallbladder, and pancreas. *Dig Dis Sci*, 1996; 41:1819-22. [PMID: 8794801]
21. Ryu JK, Ryu KH, Kim KH. Clinical features of acute acalculous cholecystitis. *J Clin Gastroenterol* 2003; 36:166-9. [PMID: 12544202]
22. Ini K, Inada H, Satoh M, Tsunoda T. Hemorrhagic acalculous cholecystitis associated with hemodialysis. *Surgery* 2002; 132:903. [PMID: 12464880]
23. Lai YC, Tarng DC. Hemorrhagic acalculous cholecystitis: an unusual location of uremic bleeding. *J Chin Med Assoc* 2009; 72:484-7. [PMID: 19762317]
24. Hiatt JR, Kobayashi MR, Doty JE, Ramming KP. Acalculous *Candida* cholecystitis: a complication of critical surgical illness. *Am Surg* 1991; 57:825-9. [PMID: 1746803]
25. Mandak JS, Pollack B, Fishman NO, Furth EE, Kochman ML, Acker MA, Lichtenstein GR. Acalculous candidal cholecystitis: a previously unrecognized complication after cardiac transplantation. *Am J Gastroenterol* 1995; 90:1333-7. [PMID: 7639242]
26. Baelen E, Roustan J. Leptospirosis associated with acute acalculous cholecystitis. Surgical or medical treatment? *J Clin Gastroenterol* 1997; 25:704-6. [PMID: 9451699]
27. Khan FY, Elouzi EB, Asif M. Acute acalculous cholecystitis complicating typhoid fever in an adult patient: a case report and review of the literature. *Travel Med Infect Dis* 2009; 7:203-6. [PMID: 19717100]
28. McCarron B, Love WC. Acalculous nontyphoidal salmonella cholecystitis requiring surgical intervention despite ciprofloxacin therapy: report of three cases. *Clin Infect Dis* 1997; 24:707-9. [PMID: 9145746]
29. West BC, Silberman R, Otterson WN. Acalculous cholecystitis and septicemia caused by non-01 *Vibrio cholerae*: first reported case and review of biliary infections with *Vibrio cholerae*. *Diagn Microbiol Infect Dis* 1998; 30:187-91. [PMID: 9572025]
30. Udayakumar D, Sanaullah N. *Campylobacter* cholecystitis. *Int J Med Sci* 2009; 1:374-5. [PMID: 19960123]
31. Kuzu MA, Ozturk Y, Ozbek H, Soran A. Acalculous cholecystitis: ascariasis as an unusual cause. *J Gastroenterol* 1996; 31:747-9. [PMID: 8887047]
32. Mansour K. Acute cholecystitis with echinococcal cyst obstruction of the common bile duct. *Postgrad Med J* 1963; 39:542-3. [PMID: 14046904]
33. Sandblom P. Hemorrhage into the biliary tract following trauma: traumatic hemobilia. *Surgery* 1948; 24:571-86. [PMID: 18884132]
34. Lin SL, Shank M, Hung YB, Ng SH, Lin CY. Choledochal cyst associated with acute acalculous cholecystitis. *J Pediatr Gastroenterol Nutr* 2000; 31:307-8. [PMID: 10997378]
35. Savoye G, Michel P, Hochain P, Savoye-Collet C, Hervé S, Del Gallo GD, Ducroté P. Fatal acalculous cholecystitis after photodynamic therapy for high-grade dysplasia of the major duodenal papilla. *Gastrointest Endosc* 2000; 51:493-5. [PMID: 10744832]
36. Cello JP. AIDS cholangiopathy: spectrum of disease. *Am J Med* 1989; 86:539-46. [PMID: 2712061]
37. French AL, Beaudet LM, Benator DA, Levy CS, Kass M, Orenstein JM. Cholecystectomy in patients with AIDS: clinicopathologic correlations in 107 cases. *Clin Infect Dis* 1995; 21:852-8. [PMID: 8645829]
38. Keshavjee SH, Magee LA, Mullen BJ, Baron DL, Brunton JL, Gallinger S. Acalculous cholecystitis associated with cytomegalovirus and sclerosing cholangitis in a patient with acquired immunodeficiency syndrome. *Can J Surg* 1993; 36:321-5. [PMID: 8396496]
39. Zar FA, El-Bayouni E, Yungbluth MM. Histologic proof of acalculous cholecystitis due to *Cyclospora cayentanesis*. *Clin Infect Dis* 2001; 33:140-1. [PMID: 11702292]
40. Souza LJ, Braga LG, Rocha Nde S, Tavares RR. Acute acalculous cholecystitis in a teenager with hepatitis A viral infection: a case report. *Braz J Infect Dis* 2009; 13:74-6. [PMID: 19578636]
41. Imamoglu M, Sarrhan H, Sari A, Ahmetoğlu A. Acute acalculous cholecystitis in children: diagnosis and treatment. *J Pediatr Surg* 2002; 37:36-7. [PMID: 11781983]
42. Parithivel VS, Gerst PH, Banerjee S, Parikh V, Albu E. Acute acalculous cholecystitis in young patients without predisposing factors. *Am Surg* 1999; 65:366-8. [PMID: 10190365]
43. Suddleson EA, Reid B, Woolley MM, Takahashi M. Hydrops of the gallbladder associated with kawasaki syndrome. *J Pediatr Surg* 1987; 22:956-959. [PMID: 3316594]
44. Bradford BF, Reid BS, Weinstein BJ, Oh KS, Girdany BR. Ultrasonographic evaluation of the gallbladder in mucocutaneous lymph node syndrome. *Radiology* 1982; 142:381-384. [PMID: 7054825]
45. Mercer S, Carpenter B. Surgical complications of Kawasaki disease. *J Pediatr Surg* 1981; 16:444-448. [PMID: 7277136]
46. Guglielmi FW, Boggio-Bertinet D, Federico A, Forte GB, Guglielmi A, Loguercio C, Mazzuoli S, et al. Total parenteral nutrition-related gastroenterological complications. *Digestive And Liver Disease* 2006; 38:623-642. [PMID: 16766237]
47. Tu YL, Yeh KW, Chen LC, Yao TC, Ou LS, Lee WI, Huang JL. Differences in disease features between childhood-onset and adult-onset in systemic lupus erythematosus patients presenting with Acute Abdominal Pain. *Semin Arthritis Rheum* 2011; 40:447-54. [PMID: 20884044]
48. Richer O, Ulinski T, Lemelle I, Ranchin B, Loirat C, Piette JC, Pillet P, et al. Abdominal manifestations in childhood-onset systemic lupus erythematosus. *Ann Rheum Dis* 2007; 66: 174-8. [PMID: 16818463]
49. Ebert EC, Hagspiel KD. Gastrointestinal and hepatic manifestations of systemic lupus erythematosus. *J Clin Gastroenterol* 2011; 45:436-41. [PMID: 21422947]
50. Kamimura T, Mimori A, Takeda A, Masuyama J, Yoshio T, Okazaki H, Kano S, et al. Acute acalculous cholecystitis in systemic lupus erythematosus. *Lupus* 1998; 7:361-3. [PMID: 9696141]
51. Mendonça JA, Marques-Neto J, Prando P, Appenzeller S. Acute acalculous cholecystitis in juvenile systemic lupus erythematosus. *Lupus* 2009; 18:561-3. [PMID: 19395459]
52. Basiratnia M, Vasei M, Bahador A, Ebrahim E, Darakhshan A. Acute acalculous cholecystitis in a child with systemic lupus erythematosus. *Pediatr Nephrol* 2006; 21:873-6. [PMID: 16575590]
53. Manuel V, Pedro GM, Cordeiro LB, de Miranda SM. Acute acalculous cholecystitis in systemic lupus erythematosus: a rare initial manifestation. *Revista Brasileira de Reumatologia (english Edition)* 2016; 56:181-4. [PMID: 27267533]
54. Shin SJ, Na KS, Jung SS, Bae SC, Yoo DH, Kim SY, Kim TH. Acute acalculous cholecystitis associated with systemic lupus erythematosus with Sjogren's syndrome. *Korean J Intern Med* 2002; 17:61-64. [PMID: 12014215]
55. Kan FY, El-Hiday AH. Acute calculous cholecystitis complicating an imported case of mixed malaria caused by *Plasmodium falciparum* and *Plasmodium vivax*: a case report. *Int J Infect Dis* 2009.
56. Elwood DR. Cholecystitis. *Surg Clin North Am* 2008; 88:1241-1252. [PMID: 18992593]
57. Kim JH, Go J, Cho CR, Kim JI, Lee MS, Park SC. First report of human acute acalculous cholecystitis caused by the fish pathogen *Lactococcus garvieae*. *J Clin Microbiol* 2013; 51:712-14. [PMID: 23241376]
58. Lalitha MK, John R. Unusual manifestations of salmonellosis-a surgical problem. *Q J Med* 1994; 87:301-9. [PMID: 7938410]

59. Ruiz-Rebollo ML, Sánchez-Antolín G, García-Pajares F, Vallecillo-Sande MA, Fernández-Orcajo P, Velicia-Llames R, Caro-Patón A. Acalculous cholecystitis due to *Salmonella enteritidis*. *World J Gastroenterol* 2008; 14:6408-9. [PMID: 19009660]
60. Savoca PE, Longo WE, Zucker KA, McMillen MM, Modlin IM. The increasing prevalence of acalculous cholecystitis in outpatients. Results of a 7-year study. *Ann Surg* 1990; 211:433-437. [PMID: 2322038]
61. Pitt HA, King W 3rd, Mann LL, Roslyn JJ, Berquist WE, Ament ME, DenBesten L. Increased risk of cholelithiasis with prolonged total parenteral nutrition. *Am J Surg* 1993; 145:106-12. [PMID: 6401411]
62. Mourani S, Dobbs SM, Genta RM, Tandon AK, Yoffe B. Hepatitis A virus associated cholecystitis. *Ann Intern Med* 1994; 120:398-400. [PMID: 8304658]
63. Siqueira VS, Alvim Ambrósio AV, Cunha PF, Furtado VM, Souza TO, Teixeira Almeida MT, Figueiredo Godoy GA, et al. Colecistite alitiásica aguda: revisão de literatura. *Rev Med Minas Gerais* 2012; 22:59-62.
64. Dhar S, Gupta R, Chrungoo RK, Sarar S, Parihar S. Acalculous cholecystitis. *JK Science* 2003; 5:146-8.
65. Laurila J. Surgically treated acute acalculous cholecystitis in critically ill patients [dissertation]. Oulu: Academic Dissertation, Faculty of Medicine, University of Oulu; 2006.
66. Vilaichone RK, Mahacha V. Tuberculous acalculous cholecystitis: a case report. *J Infect Dis Antimicrob Agent* 2005; 22:127-31.
67. Barie PS, Eachempati SR. Acute acalculous cholecystitis. *Curr Gastroenterol Rep* 2003; 5:302-9. [PMID: 12864960]
68. Iaria C, Arena L, Di Maio G, Fracassi MG, Leonardi MS, Famulari C, Cascio A. Acute acalculous cholecystitis during the course of primary Epstein-Barr virus infection: a new case and a review of the literature. *Int J Infect Dis* 2008; 12: 391-395. [PMID: 18083615]
69. Gora-Gebka M, Liberek A, Bako W, Szarszewski A, Kamin'ska B, Korzon M. Acute acalculous cholecystitis of viral etiology: a rare condition in children? *J Pediatr Surg* 2008; 43:25-7. [PMID: 18206441]
70. Prassoulia A, Panagioutou J, Vakakib M, Giannatoua I, Atilakosa A, Garoufia A, Papaevangelou V. Acute acalculous cholecystitis as the initial presentation of primary Epstein-Barr virus infection. *J Pediatr Surg* 2007; 42:11-13. [PMID: 17208530]
71. Barie PS, Eachempati SR. Acute acalculous cholecystitis. *Gastroenterol Clin North Am* 2010; 39:343. [PMID: 20478490]
72. Lau YM, Hui WM, Lau CP. Asystole complicating acalculous cholecystitis, the "Cope's sign" revisited. *Int J Cardiol* 2015; 182:447-44. [PMID: 25601766]
73. Reitz S, Slam K, Chambers LW. Biliary, pancreatic, and hepatic imaging for the general surgeon. *Surg Clin North Am* 2011; 91:59-92. [PMID: 21184901]
74. Mirvis SE, Vainright JR, Nelson AW, Johnston GS, Shorr R, Rodriguez A, Whitley NO. The diagnosis of acute acalculous cholecystitis: a comparison of sonography, scintigraphy, and CT. *AJR Am J Roentgenol* 1986; 147:1171-5. [PMID: 3535451]
75. Boland GWL, Slater G, Lu DSK, Eisenberg P, Lee MJ, Mueller PR. Prevalence and significance of gallbladder abnormalities seen on sonography in intensive care unit patients. *AJR Am J Roentgenol* 2000; 174:973-7. [PMID: 10749232]
76. Deitch EA, Engel JM. Acute acalculous cholecystitis. Ultrasonic diagnosis. *Am J Surg* 1981; 142:290-2. [PMID: 7258543]
77. Deitch EJM. Ultrasound in elective biliary tract surgery. *Am J Surg* 1980; 140:277-283. [PMID: 6773432]
78. Mirvis SE, Whitley NO, Miller JW. CT diagnosis of acalculous cholecystitis. *J Comput Assist Tomogr* 1987; 11:83-7. [PMID: 3805432]
79. Molenat F, Boussuges A, Valantin V, Sainty JM. Gallbladder abnormalities in medical ICU patients: an ultrasonographic study. *Intensive Care Med* 1996; 22:356-8. [PMID: 8708175]
80. Bilhart LE. Acalculous cholecystitis, adenomatosis, cholesterosis, and polyps of the gallbladder. In: Sleisenger MH, Fordtran JS, editors. *Gastrointestinal and liver disease*. VI edn. Philadelphia, 1999; 993-1005.
81. Mariat G, Mahul P, Prév t N, De Filippis JP, Cuilleron M, Dubois F, Auboyer C. Contribution of ultrasonography and cholescintigraphy to the diagnosis of acute acalculous cholecystitis in intensive care unit patients. *Intensive Care Med* 2000; 26:1658. [PMID: 11193273]
82. Wang AJ, Wang TE, Lin CC, Lin SC, Shih SC. Clinical predictors of severe gallbladder complications in acute acalculous cholecystitis. *World J Gastroenterol* 2003; 9:2821-3. [PMID: 14669342]
83. Inian G, Kanagalakshmi V, Kuruvilla P J. Acute acalculous cholecystitis: a rare complication of typhoid fever. *Singapore Med J* 2006; 47:327-8. [PMID: 16572247]
84. Berrington WR, Hitti J, Casper C. A case report of dengue virus infection and acalculous cholecystitis in a pregnant returning traveler. *Travel Med Infect Dis* 2007; 5:251-253. [PMID: 17574149]
85. Sugiyama M, Tokuhara M, Atomi Y. Is percutaneous cholecystostomy the optimal treatment for acute cholecystitis in the very elderly? *World J Surg* 1998; 22:459-63. [PMID: 9564288]
86. Boggi U, Di Candio G, Campatelli A, Oleggini M, Pietrabissa A, Filippini F, Bellini R, et al. Percutaneous cholecystostomy for acute cholecystitis in critically ill patients. *Hepatogastroenterology* 1999; 46:121-5. [PMID: 10228775]
87. Patterson EJ, McLoughlin RF, Mathieson JR, Cooperberg PL, MacFarlane JK. An alternative approach to acute cholecystitis. Percutaneous cholecystostomy and interval laparoscopic cholecystectomy. *Surg Endosc* 1996; 10:1185-8. [PMID: 8939839]
88. Koebrugge B, van Leuken M, Ernst MF, van Munster I, Bosscha K. Percutaneous cholecystostomy in critically ill patients with a cholecystitis: a safe option. *Dig Surg* 2010; 27: 417-21. [PMID: 20948216]
89. Vogelzang RL, Nemcek AA Jr. Percutaneous cholecystostomy: diagnostic and therapeutic efficacy. *Radiology* 1988; 168:29-34. [PMID: 3289094]
90. Kim KH, Sung CK, Park BK, Kim WK, Oh CW, Kim KS. Percutaneous gallbladder drainage for delayed laparoscopic cholecystectomy in patients with acute cholecystitis. *Am J Surg* 2000; 179:111-3. [PMID: 10773145]
91. Chopra S, Dodd GD 3rd, Mumbower AL, Chintapalli KN, Schwesinger WH, Sirinek KR, Dorman JP, et al. Treatment of acute cholecystitis in non-critically ill patients at high surgical risk: comparison of clinical outcomes after gallbladder aspiration and after percutaneous cholecystostomy. *ARJ Am J Roentgenol* 2001; 176:1025-31. [PMID: 11264103]
92. Andren-Sandberg A, Haugsvedt T, Larssen TB, Sondenaa K. Complications and late outcome following percutaneous drainage of the gallbladder in acute calculous cholecystitis. *Dig Surg* 2001; 18:393-8. [PMID: 11721115]
93. Granlund A, Karlson B-M, Elvin A, Rasmussen I. Ultrasound-guided percutaneous cholecystostomy in high-risk surgical patients. *Langenbeck Arch Surg* 2001; 386:212-7. [PMID: 11382324]
94. McLoughlin RF, Patterson EJ, Mathieson JR, Cooperberg PL, MacFarlane JK. Radiologically guided percutaneous cholecystostomy for acute cholecystitis: long-term outcome in 50 patients. *Can Assoc Radiol J* 1994; 45:455-9. [PMID: 7982107]
95. Shirai Y, Tsukada K, Kawaguchi H, Ohtani T, Muto T, Hatakeyama K. Percutaneous transhepatic cholecystostomy for acute acalculous cholecystitis. *Br J Surg* 1993; 80:1440-2. [PMID: 8252358]
96. Griniatsos J, Petrou A, Pappas P, Revenas K, Karavokyros I, Michail OP, Tsigris C, et al. Percutaneous cholecystostomy without interval cholecystectomy as definitive treatment of acute cholecystitis in elderly and critically ill patients. *South Med J* 2008; 101:586-90. [PMID: 18475218]