



Cojental Utrine Malformation

Benti Yadeta*, Ermias Bekele, Kenesa Kumera, Takele Digafe

Department of General Surgeon, Mariestope International Ethiopia, Adama Mch, Ethiopia

ABSTRACT

Uterus didelphys, also known as a duplicated uterus, is an embryological abnormality resulting from complete failure of fusion of the mullerian ducts. Usually Women with cogently uterine malformation have poor reproductive performance. We discuss a case of double uterus that previously had one successful spontaneous vaginal delivery and come for ANC follow up to our MCH clinic for 1st time. A 26 years old gravid 3, para 1 and 1 abortion mother with gestational age of 39 wk + 1 dy, presented for ANC follow up from private clinic. She had antenatal care follow up at privet clinic and referred to our MCH center with a diagnosis of term breech. Caesarean section was done in view of term breech and oligohydraminous. Intraopratively double uterus was detected after delivery of alive male neonate from left side of the uterus.

Keywords: Opioid dependence; Relapse; FELDA; ISRIM; HBM

INTRODUCTION

Mullerian Duct Anomalies (MDAs) are congenital defects of the female genital system that arise from abnormal embryological development of the mullerian ducts, these abnormalities can include failure of development, fusion, canalization or reabsorption which normally occurs between 6 and 22 weeks in uterus [1]. This condition occurs in 1% to 10% of the population, in 2% to 8% of women who are infertile and in 5% to 30% of women with a history of abortion. In uterus didelphys individual horns are fully developed normal in size with two cervices and each uterus has one fallopian tube and ovary. Patient with mullerian duct anomalies can present asymptomatic or symptomatic with infertility. In some patients, normal pregnancy can occur but obstetrical complications such as spontaneous abortion, still birth, preterm birth, malpresentation are frequent. However, the degree of these out comes varies among different types of uterine anomalies [2].

The reproductive performance of uncorent and didelphys uterus is poor compare to arcuate uterus. The chance of having term delivery for didelphy uterus was similar to that of uncornate (45%). Arcuate uterus associated with better pregnancy outcome compeer with other mularianduct anomaly with term delivery rate of 63%. A high cesarean section rate, 51% has been reported in pregnancies with didelphys uterus. Cesarean section is also recommended as a procedure of favoring especially in association with the breech presentation of the fetus [3].

The assessment and diagnoses of uterine anomaly need invasive techniques such as three dimensional ultra-sound. 3D ultra-sound had the capacity to generate accurate image of the endometrial cavity and the external contour of the uterus. Buttram V and Gibbons WE, was proposed the most widely

Received:	26-May-2020	Manuscript No:	IPGOCR-24-4299
Editor assigned:	29-May-2020	PreQC No:	IPGOCR-24-4299 (PQ)
Reviewed:	12-June-2020	QC No:	IPGOCR-24-4299
Revised:	21-June-2024	Manuscript No:	IPGOCR-24-4299 (R)
Published:	19-July-2024	DOI	10.36648/2471-8165.10.03.21

Corresponding author: Benti Yadeta, Department of General Surgeon, Mariestope International Ethiopia, Adama Mch, Ethiopia; E-mail: bentihiru@gmail.com

Citation: Yadeta B, Bekele E, Kumera K, Digafe T (2024) Cojental Utrine Malformation. Gynecol Obstet Case Rep. Vol.10 No.3:21.

Copyright: © 2024 Yadeta B, et al. This is an open-access article distributed under the terms of the Creative Commons Attribution License, which permits unrestricted use, distribution, and reproduction in any medium, provided the original author and source are credited.

and recently used classification of mullerian duct abnormalities. We report a case of double uterus in a 26 years old mother who previously had one successful vaginal delivery at term, one spontaneous abortion and didelphys uterus remained undiagnosed till she presented to us with breech presentation from privet clinic [4].

CASE PRESENTATION

A 26 years old gravid 3 para 1 and one spontaneous abortion at 1st trimester pregnancy mother presented at 39 weeks + 1 day from reliable LMP of gestation with breech presentation to our MCH clinic from privet clinic. She was give birth alive male neonate at term pregnancy without any significant complication six years back. She had antenatal care follow up at privet clinic and come to our institute with a diagnosis of term breech for her first time. Pulse rate 89/minutes, blood pressure 110/80 mmHg and temperature were in normal range pink conjunctiva, CVS and RS were normal. Routine urine and blood laboratory tests were in normal range [5].

RESULTS

Abdominal Examination

Abdominal examination was term size gravid uterus, longitudinal lie, breech presentation; fetal heart rate was in the normal range and no uterine contraction. She had an ultrasound scan report done on the same day showing term breech presentation with gestational age 38 wks + 6days, normal cardiac activity, amniotic fluid index was 3.5 cms and expected fetal weight was 3600 grams. Uterine anomaly couldn't be detected during ultrasound evaluation. Case was posted for caesarean section in view of term pregnancy with breech presentation and oligohydraminous [6].

Per Vaginal Examination

Per-vaginal examination-two cervixes felt. Both cervixes closed, posterior and uneffaced.

Per Operative Finding

Under spinal anesthesia, abdomen opened by pfannensteil incision. Transfers lower uterine segment incision was made and delivered baby presented as frank breech presentation. An alive male baby of weight 3800 gm with APGAR 9-10 was delivered from the left side of uterus and placenta delivered by complete cord traction. Uterus was exteriorize, cleanse and closed in two layers, when abdominal cavity cleansed and check for hemostat secured another none gravid uterus was found on right side and it was diagnosed as a case of double uterus. Gravid uterus had one health looking ovary and fallopian tube on left side; and none gravid uterus had one tube and ovary only on right side. Her postoperative recovery was good and she discharged on 3rd post-operative day (**Figure 1**) [7].

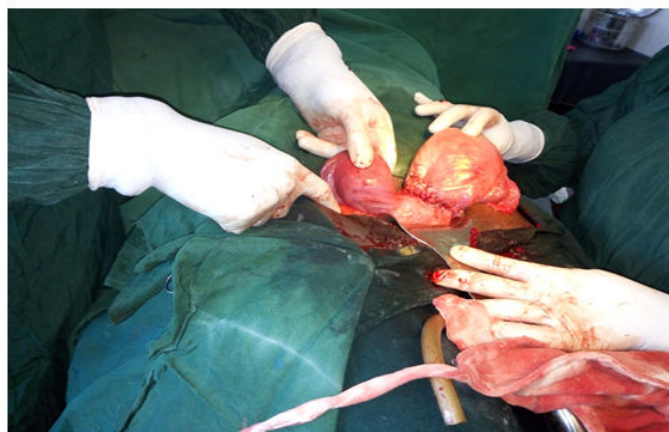


Figure 1: Intraoperative view shows uterus didelphys.

DISCUSSION

All adverse pregnancy outcomes were higher frequent in women with a congenital uterine anomalies than those with normal uterus.

The association between having a mullerian duct anomaly and fertility is debatable. The review by grimbizis conclude having MDAs may not have negative impact fertility, the incidence of MDAs in infertile women similar to that of general population and/or fertile women. Similarly reported that the incidence is similar for both infertile and general population, but the incidence is high (5%-30%) in women who had history of abortion.

A retrospective study report 1997 disagree with that of reports. Women who had history of infertility had significantly higher incidence of MDAs compare to fertile women. A case we have reported has no history of infertility [8].

The rate of prematurity was increased in women with didelphys uterus in comparison to other known studies on septate and bicornuate uteri. Similar result have been reported. In our case report she delivered by cesarean section in the 39th week and she had one previous successful spontaneous vaginal delivery at term.

Detection of uterine anomalies in early pregnancy is of great importance. Sonography has been reported to be useful in identifying abnormal uterine development in most of the cases. It was possible to detect a uterus didelphys to our case during ultrasound evaluation, but she was presented very late in term pregnancy and didelphys uterus detect intra operatively. Pregnancy located more commonly (76%) in the right uterus than in the left. The reason for this is unknown, similar to our case pregnancy located at left side of uterus.

All uterine anomalies increase the chance of fetal malpresentation at delivery. As pregnancy complication common with double uterus, mother with uterine didelphy may need special attention during pregnancy and delivery. Many of women can have normal reproductive outcomes, but intervention is recommended in the event of poor obstetric outcomes.

CONCLUSION

Uterine malformations seem to be associated with an impaired pregnancy outcome. In general, uterine anomalies do not prevent conception or implantation and women can have normal reproductive outcomes. Having uterine didelphy is not an indication for cesarean section. Breech presentation is the most common mal-presentation and an indication for cesarean delivery for women with didelphy uterus.

ACKNOWLEDGEMENT

We thanks mariestopes international Ethiopia Adama branch for give us full data of patient.

CONFLICT OF INTEREST

The authors did not report any potential conflict of interests.

REFERENCES

1. Heinonen PK (1984) Uterus didelphys: A report of 26 cases. *Eur J Obstet Gynecol Reprod Biol.* 17(5):345-350.
2. Heinonen PK (2000) Clinical implications of the didelphic uterus: Long-term follow-up of 49 cases *Eur J Obstet Gynecol Reprod Biol.* 91(2):183-190.
3. Raga F, Bauset C, Remohi J, Bonilla-Musoles F, Simon C, et al. (1997) Reproductive impact of congenital mullerian anomalies. *Hum Reprod.* 12(10):2277-2281.
4. Grimbizis GF, Camus M, Tarlatzis BC, Bontis JN, Devroey P (2001) Clinical implications of uterine malformations and hysteroscopic treatment results. *Hum Reprod Update.* 7(2):161-174.
5. Chan YY, Jayaprakasan K, Tan A, Thornton JG, Coomarasamy A, et al. (2011) Reproductive outcomes in women with congenital uterine anomalies: A systematic review. *Ultrasound Obstet Gynecol.* 38(4):371-382.
6. Acien P (1993) Reproductive performance of women with uterine malformations. *Hum Reprod.* 8(1):122-126.
7. Woelfer B, Salim R, Banerjee S, Elson J, Regan L, et al. (2001) Reproductive outcomes in women with congenital uterine anomalies detected by three-dimensional ultrasound screening. *Obstet Gynecol.* 98(6):1099-1103.
8. Raga F, Bonilla-Musoles F, Blanes J, Osborne NG (1996) Congenital mullerian anomalies: Diagnostic accuracy of three-dimensional ultrasound. *Fertil Steril.* 65(3): 523-528.