

## Internal Breast Reduction Surgery **Huacuja AA\*, Montalvo AA and Montalvo DA**

**Received:** December 12, 2017; **Accepted:** December 27, 2017; **Published:** January 05, 2018

Dermatology Clinic and Aesthetic Surgery of Puebla, Puebla, Mexico

### Introduction

Nowadays, some people regret having a breast augmentation surgery, considering their implants oversized and not natural looking. However, the decision of having a reduction procedure is not easy, due to the fact that it implies more skin scarring.

Some patients would like to reduce their implant dimensions about one or two sizes without having a new scar. Considering the skin and muscle previously involved, this presents as a problem for the surgeon, who has to perform a technique without long or bigger scars [1].

Therefore, we have developed a new technique, which allows us to perform an easy and efficient implant volume reduction avoiding the scar consequences of a breast lift surgery.

To achieve this procedure, we require that the patient fulfils the following requirements:

The implants must have been placed behind the pectoral muscle **Figure 1**.

1. The patient's skin should have a thick dermis layer.
2. Pregnancy or drastic weight change might affect surgery's results.
3. The nipple-areola complex may require a certain height reposition depending on the breast characteristics.
4. The technique won't be helpful if the reduction is above two sizes.

### Technique

To initiate, the breast area involved is infiltrated with a dilution of adrenaline and physiologic solution (1:10, 000). The next step is to perform an incision right at the same place where the previous scar has been made, allowing us to remove the previous scar completely [2].

The tissue is dissected up to the implant until the implant is released, removed and exchanged for a smaller size **Figure 2**.

All the extra space left from the previous implant is sutured together in a circular fashion with Vicryl 1-0. Hemostasis is reviewed, and a smaller implant is inserted.

### \*Corresponding author:

Aristides Arellano Huacuja

✉ aristidesarella@yahoo.com.mx

MD, FICS, Plastic Surgeon, Dermatology Clinic and Aesthetic Surgery of Puebla, Puebla, Mexico.

**Tel:** (52) (222) 2669169

**Citation:** Huacuja AA, Montalvo AA, Montalvo DA (2018) Internal Breast Reduction Surgery. J Healthc Commun Vol.3 No.1:18

Continuing to close the pectoral muscle's fibrosis capsule with the superficial fascia of the chest wall. There is no need to perform a capsulotomy. Sometimes we create a pocket under the breast tissue, over the fascia muscle [3].

The nipple-areola complex is repositioned 1-2 cm above the original place in order to live it higher. When needed, we suture the nipple-areola complex at the central or side level with Monocryl 3-0.

At least, the skin is closed with Histoacryl glow.

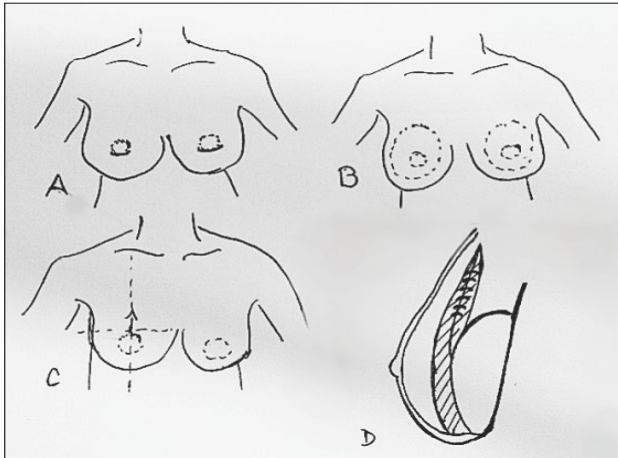
### Aftercare

The use of post-surgical bra for 30 days is recommended, also back sleeping, general care of mammoplasty and avoiding any type of strength effort.

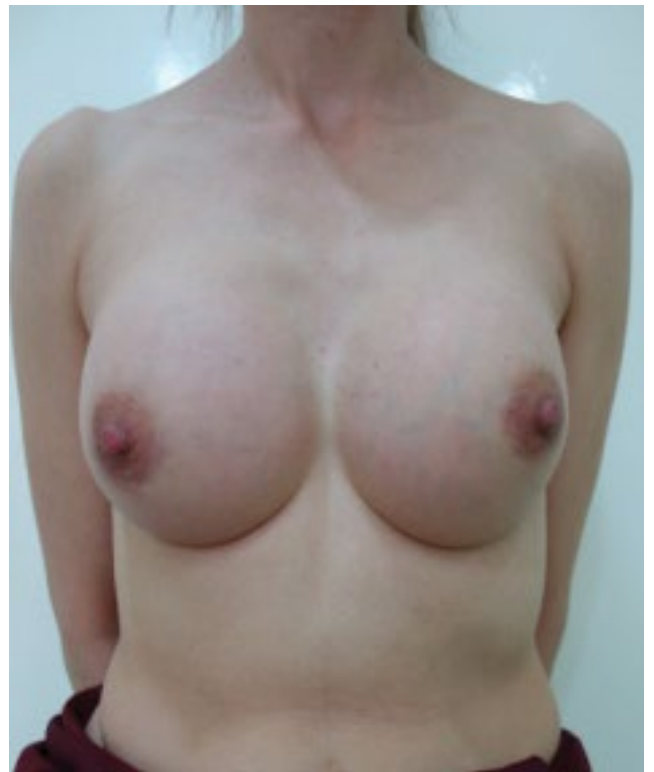### Conclusion

The proposed technique allows breast reduction with smaller implants without increasing the number and size of scars, which is very pleasant for the patients, and requires less recovery time **Figures 3-14**.

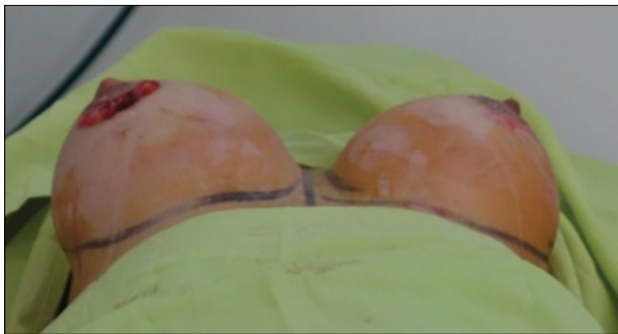It also allows to relocate the crease of the breast and maintain the implant and tissue in the right position.



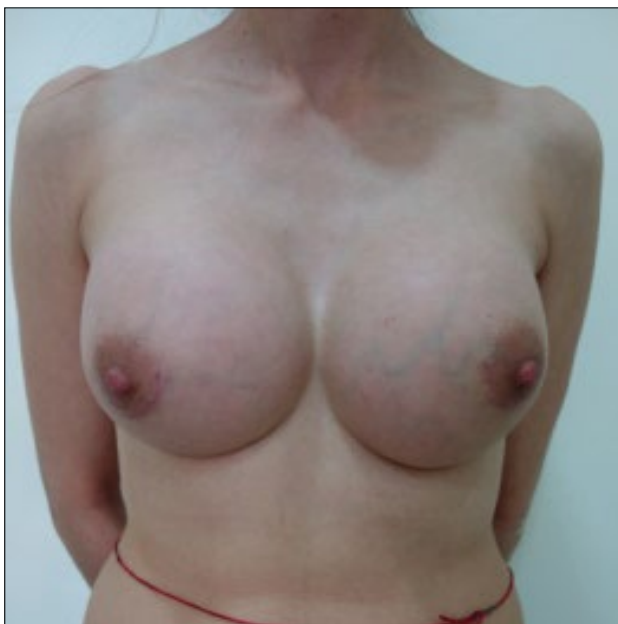**Figure 1** A) Marking areola. B) Marking breast reduction C) Lifting the nipple- areola complex D) Suture the chest muscle.




**Figure 4** After surgery 370 cc.



**Figure 2** Left breast implant smaller.



**Figure 3** Before surgery 550 cc.



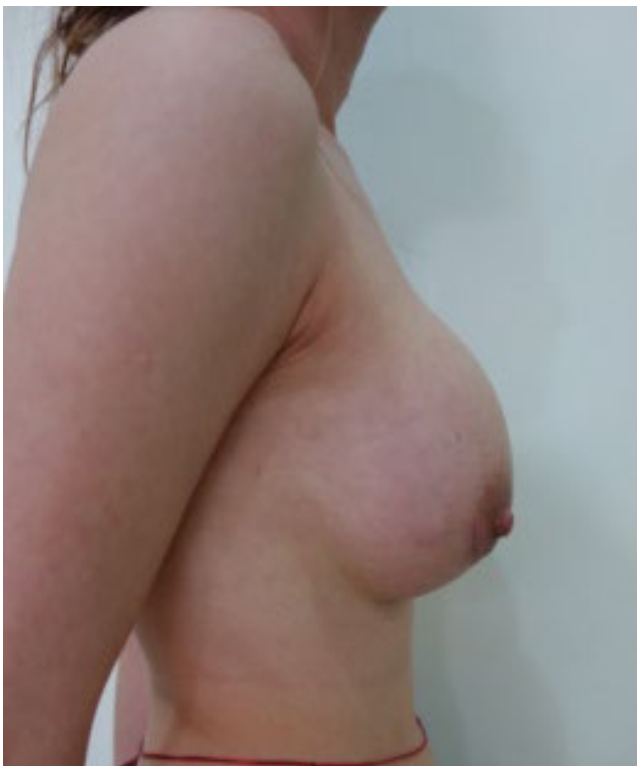**Figure 5** Before surgery 550 cc.




**Figure 6** After surgery 370 cc.



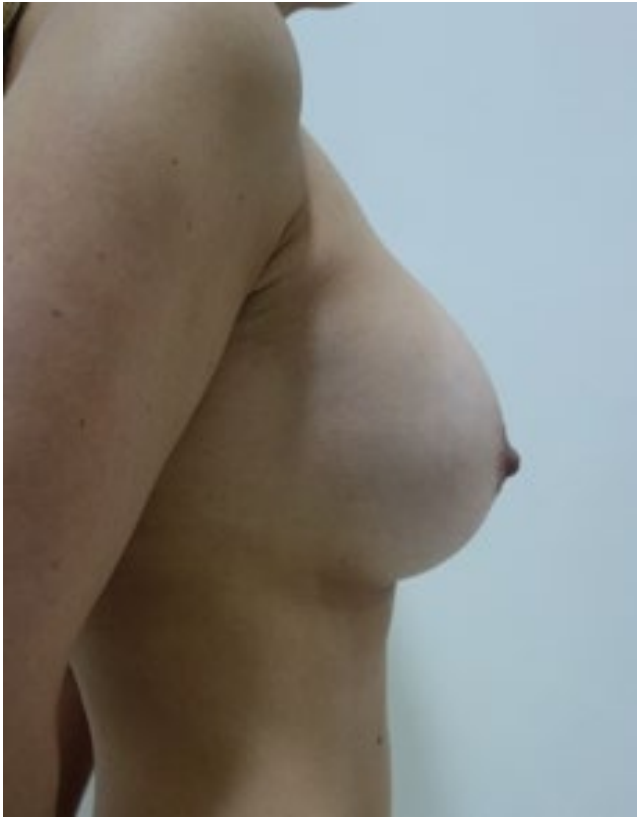
**Figure 8** After surgery 370 cc.



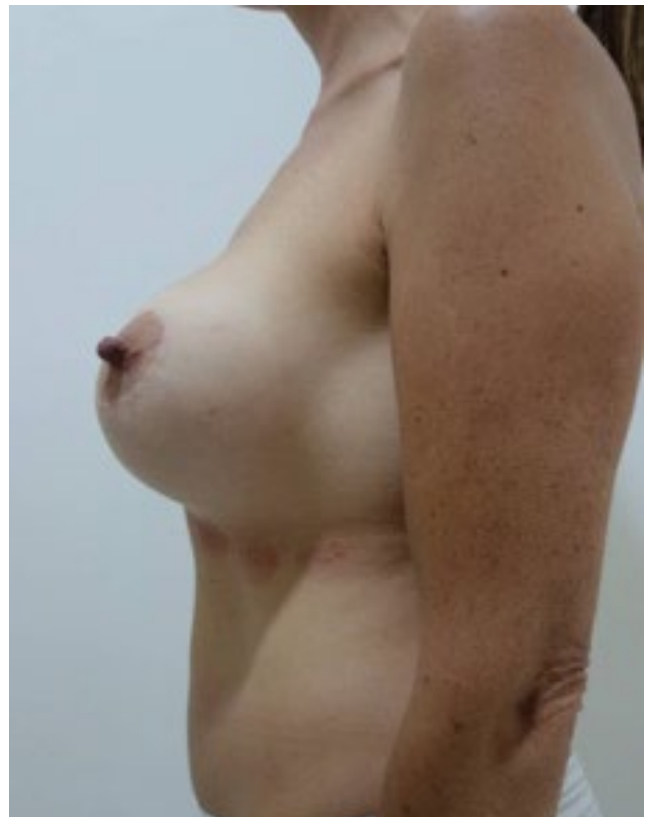
**Figure 7** Before surgery 550 cc.



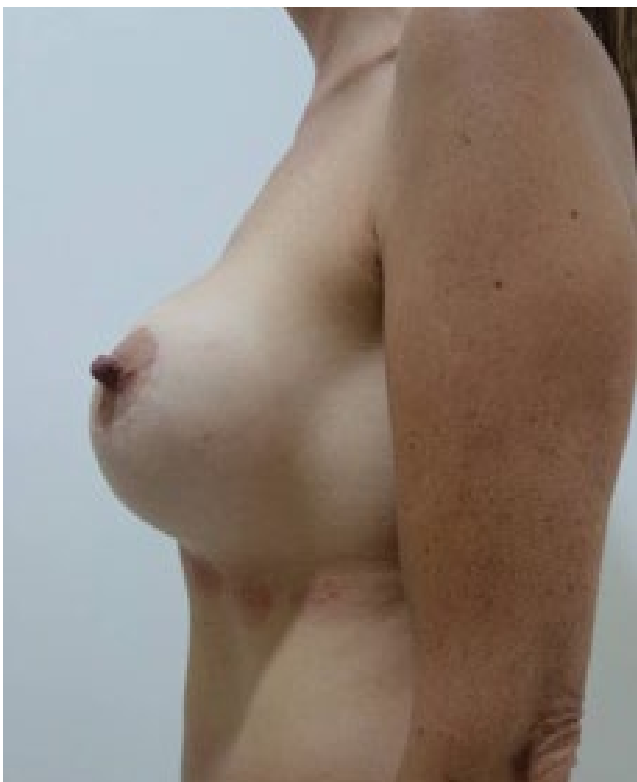**Figure 9** Before surgery 480 cc.



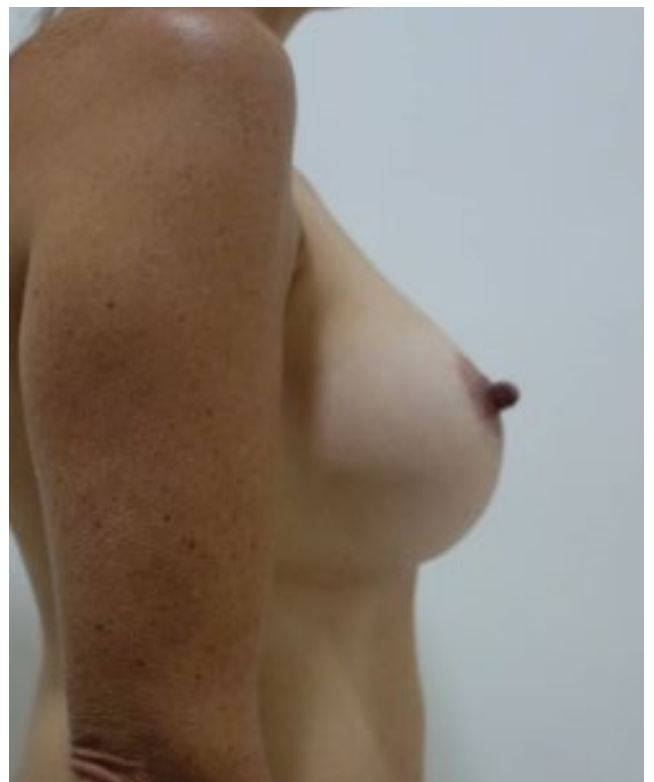
**Figure 10** After surgery 370 cc.



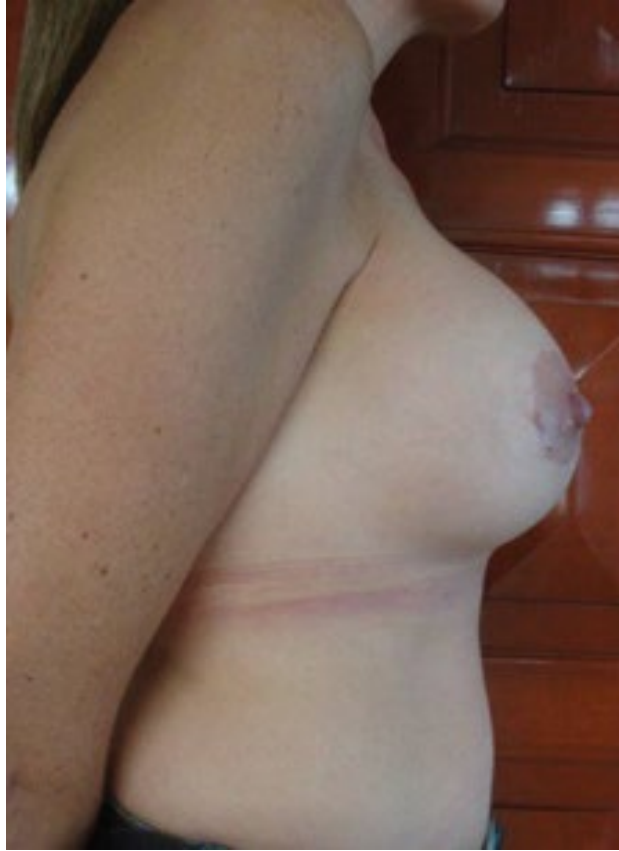**Figure 12** After surgery 370 cc.



**Figure 11** Before surgery 480 cc.



**Figure 13** Before surgery 480 cc.



**Figure 14** After surgery 370 cc.

## References

- 1 Intriago MY, Tejada PE, Polit EYV (2013) Mamoplastia de reducción con cicatrices pequeñas para grandes hipertrofias mamarias o gigantomastias. *Cir plást iberolatinoam* 39: 1-8.
- 2 Ali A, Zuleta-Bechara C, Vassaro V (2013) Colgajo dermoglandular de apoyo en mastopexia con implantes. Técnica de la hamaca. *Cir plást iberolatinoam* 39: 361-368.
- 3 Nina L, Rocío M (2014) Aesthetic breast surgery. *Rev Act Clin Med* 47: 2503-2508.