

CASE REPORT

Case Report of Mannose-Binding Lectin (MBL) Deficiency and Postoperative Sepsis and Coagulopathy in a Patient Following Total Pancreatectomy for Chronic Pancreatitis

Wen Yuan Chung, Amar M Eltweri, Gianpiero Gravante, Ali Arshad, Cristina A Pollard, Matthew S Metcalfe, Ashley R Dennison

Department of Hepatobiliary and Pancreatic Surgery, University Hospitals of Leicester, Leicester, UK

ABSTRACT

Context Complement plays a central role against infection and coordinates the activity of coagulation and fibrinolysis. In this report we present a patient that underwent total pancreatectomy experienced sepsis, coagulopathy and bleeding that endangered the postoperative course. **Case report** A sixty-five-year-old woman underwent total pancreatectomy for intractable pain without islet transplant, this patient was diagnosed as AP and MBL deficient from a blood test performed preoperatively. On the postoperative course she experienced severe haemorrhages and sepsis for 3 weeks postoperatively. An analysis of serial perioperative serum samples conducted which showed further depletion of the alternate and MBL complement pathway without restoration to baseline levels. **Conclusion** This is the first reported case of alternative and mannose-binding lectin pathways depletion associated with major postoperative bleeding and sepsis following pancreatic surgery. Future research should examine the relationship between complement pathways activity and postoperative complications in order to possibly introduce it as a preoperative screening and possible replacement therapy prior to any major surgical intervention.

INTRODUCTION

Complement plays a central role against infection and coordinates the activity of other homeostatic systems such as coagulation and fibrinolysis. Essentially, it can be initiated by three discrete but related cascades which are the classical, alternative and mannose-binding lectin (MBL) pathways [1]. The binding of natural antibodies to microbial surfaces activates the classical complement activation pathway, which is supported and amplified by two antibody-independent complement activation routes, the MBL and the alternative pathway [2]. The depletion of a complement pathway may reflect the increased activation and consumption of the complement proteins, such as in cases of severe peritonitis [2], where all the three components are activated and consumed to a different extent.

Genetic deficiencies of one or more of the complement activation pathways, predisposes to infection, sepsis and may contribute to increased mortality. Deficiency in MBL pathway activity is present in 5-30% of the population [3]. Its presence has been associated with predisposition to infections of the respiratory tract [4, 5], infected burns [6], tuberculosis [7] or infections following invasive procedures such as stem cell [8-10] and liver transplantation [11,

12]. The relationship between complement and other protease cascades involves also the coagulation cascade as evidenced by MBL-associated proteases which have coagulation-stimulating activities [13]. The activation of MBL-associated serine protease 1 has thrombin-like activity that cleaves and activates fibrinogen and factor XIII [14], while MBL-associated serine protease 2 is capable of promoting fibrinogen turnover by cleavage of prothrombin, generating thrombin that in turn cleaves both factor XIII and fibrinogen forming cross-linked fibrin [15]. MBL deficiency has been shown to be associated with significant coagulopathy leading to disseminated intravascular coagulation and the systemic inflammatory response syndrome [3,13,16]. We present the case of a patient with alternative and MBL complement depletion undergoing total pancreatectomy in our institution that experienced these significant postoperative complications.

CASE REPORT

A 65-year-old female was referred to the Hepatobiliary Department of the Leicester General Hospital (LGH) with a one year history of refractory upper abdominal pain, nausea, steatorrhoea, and weight loss (49 kg BMI 19.1 kg/m²). She has a past medical history of diabetes mellitus on gliclazide 80 mg twice a day and metformin 500 mg twice a day (latest HBA1c=7.5). She had previous CT scan which showed a cystic lesion in the body of the pancreas with partially calcified walls 'pseudopancreatic cyst'. At our institution she underwent further investigations to rollout any neoplastic changes, these were including: a magnetic resonance cholangiopancreatogram, a laparoscopic intraoperative ultrasound and two additional CT scans performed after 2 and 5 months to see if there were any interval changes in the cyst size and appearance. All these

Received April 13th, 2014 – Accepted September 2nd, 2014

Key words Mannose binding lectin complement pathway; Pancreatectomy; Chronic Pancreatitis

Correspondence Wen Yuan Chung

Department of Hepatobiliary and Pancreatic Surgery

Leicester General Hospital

Gwendolen Road, Leicester LE5 4PW, UK

Phone: +441162588244

Fax: +441162588244

E-mail wenchung813@btinternet.com

investigations confirmed the benign nature of the lesion on the background of chronic pancreatitis, and faecal elastase levels that were diagnostic of pancreatic insufficiency (15 µg/g).

MANAGEMENT

The patient commenced on Pancrelipase capsules, opiate analgesia and required a splanchnic nerve block in April 2009 under X-ray guidance with radiofrequency ablation for the refractory pain management. Unfortunately this only achieved pain control for 6 weeks; she was also experiencing worsening diabetic control requiring insulin treatment. Therefore the patient was eligible for our institution preoperative evaluation programme for total pancreatectomy which included a consultation with gastroenterologist, general physician, psychologist, anaesthetic and pain management team and also after meeting with at least two patients who had previously had total pancreatectomy. As she met our institutional criteria and gave her consent for total pancreatectomy; on October 2010 she underwent total pancreatectomy. Intra-operative findings were a grossly inflamed large cystic lesion replacing the head and body of the pancreas gland with a distal atrophic tail. There was also dense fibrosis and oedema surrounding the pancreas and a very small hypoplastic spleen. At the end of the procedure, haemostasis was maintained and the patient transferred to the Intensive Care Unit on insulin sliding scale for glycaemic and epidural infusion for pain control. Histology from the resected specimen revealed chronic pancreatitis with an early-stage pancreatic cancer (T2 N0 R0) microscopically clear resection margins.

POSTOPERATIVE PERIOD

On the first postoperative day some haemoserous fluid was present in the right abdominal drain that was managed conservatively as the patient was haemodynamically stable. On the second postoperative day, she received one unit of red blood cells and platelets. At the 6th postoperative day there was no evidence of bleeding and her haemoglobin was 9.5 g/dl. On the 7th postoperative day she was started on nasogastric feeding and she received 20% human albumin solution intravenously for low albumin level of 11 g/l. A liver ultrasound scan was organised for slightly deranged liver function test (bilirubin 13 micromol/l, alanine transaminase 21 IU/L alkaline phosphatase 436 IU/L), and the scan was normal. On the 10th postoperative day the patient experienced abdominal distension, vomiting and right shoulder tip pain with raised white cell count of 15.5×10^9 . Hence, she was started on intravenous antibiotics (Tazocin®, Pfizer Inc., New York, NY, USA; 4.5 g) three times a day. CT scan abdomen and pelvis revealed a large retroperitoneal haematoma and a paralytic ileus was present that required parenteral nutrition. Thirteen days postoperatively the patient was clinically improving and the paralytic ileus began to resolve, therefore she was commenced on oral fluids that were tolerated. Eighteen days postoperatively, the patient experienced an episode of hematemesis; therefore she was commenced on a proton pump inhibitor, octreotide, glutamine and propranolol to reduce the splanchnic perfusion pressure. A gastroscopy

was performed and showed mild gastritis but no stress ulcers or active bleeding. However, during the night some purulent fluid was evident in the right abdominal drain and so she was recommenced on intravenous fluids and antibiotics (imipenem). On the 22nd postoperative day she was afebrile, with normal vital observations, the gut function progressively improved (tolerated all fluids and started passing some flatus), able to mobilize and she was eating without nausea or vomiting.

COMPLEMENT ANALYSIS

Classical, alternative and MBL complement pathway activities were assessed with the enzyme immunoassay Wieslab™ complement system screen kit (Euro-Diagnostica AB, Sweden). TAP was measured with the enzyme-linked immunosorbent assay (ELISA) kit (USCN, Life Science Inc. China). Inflammatory cytokines such as Interleukin (IL) IL-1α, IL-6, and tumor necrosis factor (TNF)-α were measured as pro-inflammatory markers using Luminex 29-plex kit (Baylor Research Institute, US).

RESULT

The AP and MBL complement pathways showed hypoactivity and hence consumption after surgery. The patient subsequently did not have a restoration of activity to baseline levels (Figure 1). Furthermore, the TAP concentration increased to 20 mmol/l during surgery and peaked at the 1st postoperative hour. Similar results were obtained for pro-inflammatory cytokines examined (Figure 2).

DISCUSSION

Intractable pain is a disabling symptom of chronic pancreatitis that may require surgical resection of the entire gland (total pancreatectomy) when all the other attempts of management have failed [17, 18]. The postoperative mortality rate of total pancreatectomy is high (0-16%) [19, 20], and half of all deaths are due to major surgical complications (39-51%) [19, 20] such as intra-abdominal abscesses (8%), leaks of the biliodigestive anastomosis (3%) and significant postoperative haemorrhage (3%) from the splenic or left gastric arteries [19]. Due to the high rates of postoperative mortality and significant morbidity it is desirable preoperatively to identify those patients who may harbour a particular predisposition to developing of these complications so that appropriate counselling and measures could be established to try to prevent them after surgery.

In our experience at this institution this was the first patient underwent total pancreatectomy and had this postoperative course characterised by infection, sepsis, and bleeding [21, 22]. There were hypoactivity of AP and MBL pathways present throughout the entire postoperative period, even though the AP activity recovered to approximately 20% of baseline after few days, but the MBL never recovered. The complement pathways have been linked to postoperative sepsis and haemorrhages, two complications experienced by our patient with AP and MBL activity depletion. Higher values of TAP have been already associated with postoperative pancreaticoduodenal fistulas following

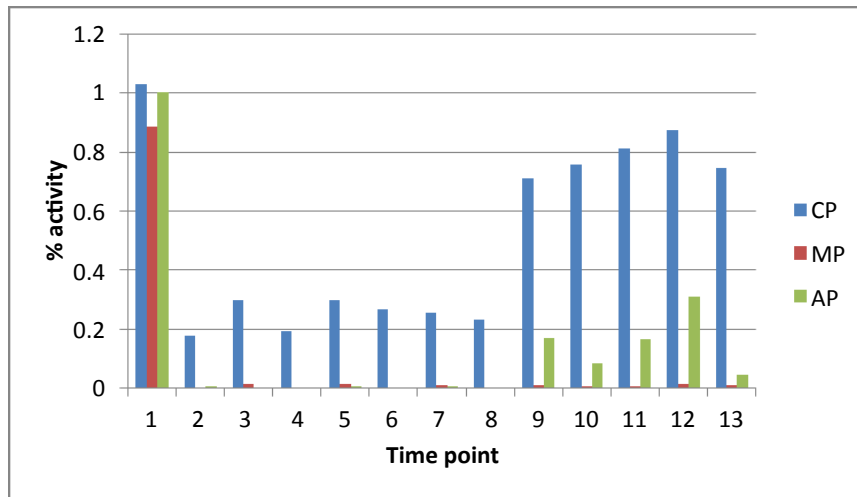


Figure 1. Complement activity in MBL deficient patient undergoing total pancreatectomy (CP = Classical pathway, MP = Mannose-binding Lectin pathway, AP = Alternative pathway). Time points: during induction of anaesthesia (1), end of pancreatectomy (2), post islet infusion or end of surgery (3), 1st, 3rd and 5th postoperative hours (4-6), 1st to 7th postoperative day (7-13).

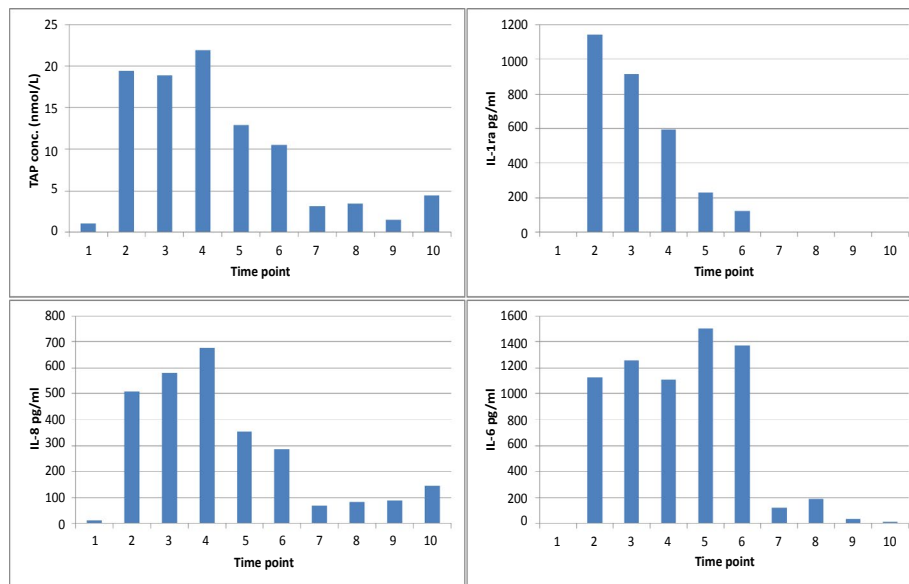


Figure 2. Concentration of trypsinogen activation peptide (TAP) and proinflammatory cytokines investigated (IL-1, IL-6 and IL-8) in MBL deficient patient. Time points: during induction of anaesthesia (1), end of pancreatectomy (2), end of surgery (3), 1 hr, 3 hrs & 5 hrs (4-6), Day 1-4 (7-10).

pancreaticoduodenectomy [23], pancreatic injury [24], and severity of acute pancreatitis [25, 26]. However, our patient underwent total pancreatectomy and no pancreatic tissue was left to stimulate TAP production following the operation. Even accounting for this, the rise of TAP was unexpectedly higher in the AP and MBL depleted patient. Although no report is available in the literature of an eventual link between the AP and MBL pathways depletion and TAP levels, it is possible that in these patients the higher values of TAP reflect the influence that complement has on the other homeostatic cascades including coagulation.

Similar considerations can be made for the other inflammatory markers investigated: all were elevated in this patient with AP and MBL deficiency. Higher levels of IL-6 and IL-8 are known to be associated with severe acute pancreatitis [25, 26], however increased production is also present in MBL deficiency [16, 27]. It seems that MBL deficiency may in fact confer favourable outcomes in patients who undergo operations that produce a significant postoperative systemic inflammatory reaction with potential for adverse effects [28]. In MBL deficiency

it is possible that the higher TAP concentrations directly stimulate the production of inflammatory markers [29]. Our patient had the entire pancreas removed and it is unlikely that the postoperative production of inflammatory markers is due to pancreatic inflammation. The higher concentrations produced of both TAP and inflammatory markers in the AP and MBL depleted patient confirm the link of the AP and the MBL pathways with the other homeostatic cascades (complement and coagulation) as suggested already by Takayashi *et al* [13, 16].

It is difficult from one patient to draw an association or correlation and it is unclear as to if this is more than a coincidence until a significant number of patients who consistently correlate this pathway deficiency with increased complications can be proved. For these reasons our findings should now stimulate future studies to investigate this issue further as well as the eventual beneficial effects of screening preoperatively the three complement activities with appropriate stimuli. In fact, it would be useful to identify patients predisposed to the development of postoperative sepsis and disturbances of

the coagulation cascade after major surgery [28] in order to potentially administer complement components pre-operatively to prevent major postoperative complications [30].

CONCLUSION

We add to the literature the relationship between AP and MBL deficiency with major postoperative complications and we report the first case following total pancreatectomy. We believe that the development of complications could be driven by altered complement activation ultimately involving other homeostatic mechanisms including the coagulation cascade and the inflammatory response. Later prospective studies are now necessary to investigate these results further in order to propose the value of preoperative screening of AP and MBL activities after appropriate stimuli to anticipate significant postoperative complications after major surgery.

Conflicts of Interest

The authors declare no conflict of interest

REFERENCE

1. Eisen DP, Minchinton RM. Impact of mannose-binding lectin on susceptibility to infectious diseases. *Clin Infect Dis.* 2003; 37: 1496-1505. [PMID:14614673]
2. Windbichler M, Echtenacher B, Hehlgans T, Jensenius JC, Schwaeble W, Mannel DN. Involvement of the lectin pathway of complement activation in antimicrobial immune defense during experimental septic peritonitis. *Infect Immun.* 2004; 72: 5247-5252.
3. Garred P, Larsen F, Madsen HO, Koch C. Mannose-binding lectin deficiency--revisited. *Mol Immunol.* 2003; 40: 73-84. [PMID:12914814]
4. Eisen DP. Mannose-binding lectin deficiency and respiratory tract infection. *J Innate Immun.* 2010; 2: 114-122. [PMID:20375630]
5. Chang WC, White MR, Moyo P, McClear S, Thiel S, *et al.* Lack of the pattern recognition molecule mannose-binding lectin increases susceptibility to influenza A virus infection. *BMC immunology.* 2010; 11: 64.
6. Moller-Kristensen M, Ip WK, Shi L, Gowda LD, Hamblin MR, *et al.* Deficiency of mannose-binding lectin greatly increases susceptibility to postburn infection with *Pseudomonas aeruginosa*. *J Immunol.* 2006; 176: 1769-1775. [PMID:16424207]
7. Denholm JT, McBryde ES, Eisen DP. Mannose-binding lectin and susceptibility to tuberculosis: a meta-analysis. *Clin Exp Immunol.* 2010; 162: 84-90. [PMID:20636396]
8. Granell M, Urbano-Ispizua A, Suarez B, Rovira M, Fernandez-Aviles F, *et al.* Mannan-binding lectin pathway deficiencies and invasive fungal infections following allogeneic stem cell transplantation. *Exp Hematol.* 2006; 34: 1435-1441. [PMID:16982337]
9. Mullighan CG, Heatley S, Doherty K, Szabo F, Grigg A, *et al.* Mannose-binding lectin gene polymorphisms are associated with major infection following allogeneic hemopoietic stem cell transplantation. *Blood.* 2002; 99: 3524-3529. [PMID:11986203]
10. Mullighan CG, Bardy PG. Mannose-binding lectin and infection following allogeneic hemopoietic stem cell transplantation. *Leuk Lymphoma.* 2004; 45: 247-256. [PMID:15101708]
11. Worthley DL, Johnson DF, Eisen DP, Dean MM, Heatley SL, *et al.* Donor mannose-binding lectin deficiency increases the likelihood of clinically significant infection after liver transplantation. *Clin Infect Dis.* 2009; 48: 410-417. [PMID:19143554]
12. Bouwman LH, Roos A, Terpstra OT, de Knijff P, van Hoek B, *et al.* Mannose binding lectin gene polymorphisms confer a major risk for severe infections after liver transplantation. *Gastroenterology.* 2005; 129: 408-414. [PMID:16083697]
13. Takahashi K. Mannose-binding lectin and the balance between immune protection and complication. *Expert Rev Anti Infect Ther.* 2011; 9: 1179-1190. [PMID:22114968]
14. Gulla KC, Gupta K, Krarup A, Gal P, Schwaeble WJ. Activation of mannan-binding lectin-associated serine proteases leads to generation of a fibrin clot. *Immunology.* 2010; 129: 482-495.
15. Krarup A, Wallis R, Presanis JS, Gal P, Sim RB. Simultaneous activation of complement and coagulation by MBL-associated serine protease 2. *PLoS one* 2007; 2: e623.
16. Takahashi K, Chang WC, Takahashi M, Pavlov V, Ishida Y, *et al.* Mannose-binding lectin and its associated proteases (MASPs) mediate coagulation and its deficiency is a risk factor in developing complications from infection, including disseminated intravascular coagulation. *Immunobiology.* 2011; 216: 96-102. [PMID:20399528]
17. Chauhan S, Forsmark CE. Pain management in chronic pancreatitis: A treatment algorithm. *Best Pract Res Clin Gastroenterol.* 2010; 24: 323-335. [PMID:20510832]
18. Gachago C, Draganov PV. Pain management in chronic pancreatitis. *World J Gastroenterol.* 2008; 14: 3137-3148.
19. Janot MS, Belyaev O, Kersting S, Chromik AM, Seelig MH, *et al.* Indications and early outcomes for total pancreatectomy at a high-volume pancreas center. *HPB Surg.* 2010.
20. Crippa S, Tamburrino D, Partelli S, Salvia R, Germenia S, *et al.* Total pancreatectomy: indications, different timing, and perioperative and long-term outcomes. *Surgery.* 2011; 149: 79-86. [PMID:20494386]
21. Webb MA, Illouz SC, Pollard CA, Gregory R, Mayberry JF, *et al.* Islet auto transplantation following total pancreatectomy: a long-term assessment of graft function. *Pancreas.* 2008; 37: 282-287. [PMID:18815550]
22. Garcea G, Weaver J, Phillips J, Pollard CA, Ilouz SC, *et al.* Total pancreatectomy with and without islet cell transplantation for chronic pancreatitis: a series of 85 consecutive patients. *Pancreas.* 2009; 38: 1-7. [PMID:18665009]
23. Ansoorge C, Regner S, Segersvard R, Strommer L. Early intraperitoneal metabolic changes and protease activation as indicators of pancreatic fistula after pancreaticoduodenectomy. *Br J Surg.* 2012; 99: 104-111. [PMID:22052299]
24. Kaphalia BS, Bhopale KK, Kondraganti S, Wu H, Boor PJ, *et al.* Pancreatic injury in hepatic alcohol dehydrogenase-deficient deer mice after subchronic exposure to ethanol. *Toxicol Appl Pharmacol.* 2010; 246: 154-62. [PMID:20478324]
25. Rau B, Schilling MK, Beger HG. Laboratory markers of severe acute pancreatitis. *Dig Dis.* 2004; 22: 247-257. [PMID:15753607]
26. Werner J, Hartwig W, Uhl W, Muller C, Buchler MW. Useful markers for predicting severity and monitoring progression of acute pancreatitis. *Pancreatology.* 2003; 3: 115-127. [PMID:12748420]
27. Dean MM, Flower RL, Eisen DP, Minchinton RM, Hart DN, *et al.* Mannose-binding lectin deficiency influences innate and antigen-presenting functions of blood myeloid dendritic cells. *Immunology.* 2011; 132: 296-305. [PMID:21091907]
28. Fiane AE, Videm V, Lingaas PS, Heggelund L, Nielsen EW, *et al.* Mechanism of complement activation and its role in the inflammatory response after thoracoabdominal aortic aneurysm repair. *Circulation.* 2003; 108: 849-856. [PMID:12900342]
29. Heath DI, Cruickshank A, Gudgeon AM, Jehanli A, Shenkin A, *et al.* The relationship between pancreatic enzyme release and activation and the acute-phase protein response in patients with acute pancreatitis. *Pancreas.* 1995; 10: 347-353. [PMID:7540760]
30. Garred P, Pressler T, Lanng S, Madsen HO, Moser C, *et al.* Mannose-binding lectin (MBL) therapy in an MBL-deficient patient with severe cystic fibrosis lung disease. *Pediatr Pulmonol.* 2002; 33: 201-207. [PMID:11836800]