

CASE REPORT

Dorsal Pancreatic Agenesis

Oya Uygur-Bayramiçli¹, Resat Dabak², Gamze Kiliçoglu³, Can Dolapçioğlu¹, Derya Öztas¹

Departments of ¹Gastroenterology and ²Family Medicine, Kartal State Hospital;
³Department of Radiology, Haydarpaşa Numune Hospital. Istanbul, Turkey

ABSTRACT

Context Agenesis of the dorsal pancreas is a rare entity and might present with various symptoms. We report a case which presented with chronic pancreatitis.

Case report The patient presented with epigastric pain and we found dorsal pancreatic agenesis causing chronic pancreatitis.

Conclusions Dorsal pancreatic agenesis can be easily diagnosed with new techniques and its association with clinical syndromes can be better understood.

INTRODUCTION

During the complex embryologic development of the pancreas, several morphologic anomalies can develop. One of these anomalies is complete agenesis of the dorsal pancreas which is a rare entity and has been reported in the literature only as case reports. This congenital anomaly is accepted mostly as an anatomic variation but it may cause some symptoms such as non-specific abdominal pain and diabetes mellitus [1]. We present a case of dorsal pancreatic agenesis presenting as chronic pancreatitis.

CASE REPORT

A 44-year-old male patient presented with epigastric pain of a two week duration which worsened after meals. In these two weeks, the patient had lost 4 kg as a result of decreased

food intake due to a fear of pain; he also had loose stools. The patient said that he had had three similar pain episodes in the last two years. The past medical records of the patient revealed that he had had mild hyperamylasemia and leukocytosis during those episodes, but they resolved spontaneously after one to two weeks and the patient had not received any treatment. Abdominal ultrasound was said "to be normal" but the images were not available. On physical examination, everything was normal except for abdominal distension. There was no family history of pancreatitis or diabetes and he himself did not have a history of diabetes. He did not drink alcohol or smoke and he did not use any drugs on a regular basis. The biochemical evaluation of the patient revealed hyperamylasemia (250 IU/L; reference range: 30-115 IU/L), leukocytosis (12,000 mm⁻³; reference range: 4,000-11,000 mm⁻³) and a mild elevation of fasting plasma glucose (135 mg/dL; reference range: 80-115 mg/dL). A Van de Kamer test, transaminase, alkaline phosphatase, gamma glutamyl-transferase, bilirubin, CRP, lipase and CA 19-9 levels were normal. An abdominal ultrasound was performed which showed a large dense pancreatic head. An upper abdominal MRI and MRCP were carried out with the suspicion of a pancreatic malignancy. T2-weighted axial MRI images demonstrated that the pancreatic head and neck were normal in size and shape; however, the body and tail were inexistent. At MRCP, the major pancreatic duct was short and the dorsal duct

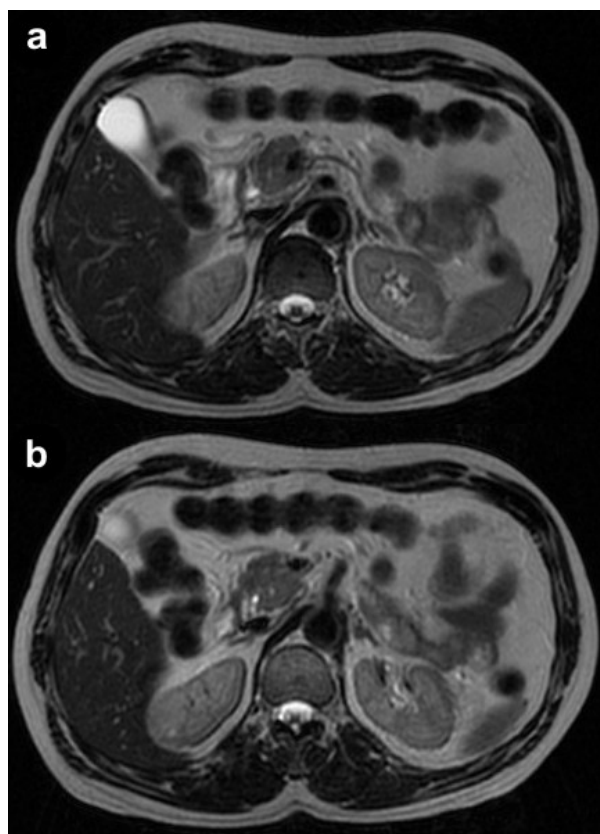


Figure 1. Abdominal MRCP showing a short major pancreatic duct and no visualized dorsal duct.

could not be visualized. These findings were compatible with the diagnosis of dorsal pancreatic agenesis (Figure 1). The patient was diagnosed as having chronic relapsing pancreatitis based on the recurrent clinical symptoms and laboratory values. We could not identify any toxins, or metabolic or autoimmune disorders which may have caused chronic pancreatitis. The pain resolved after 10 days on a low-fat diet; his diabetes was also controlled with diet.

The patient had two more episodes of epigastric pain and hyperamylasemia in the following 12 months but they also resolved spontaneously.

DISCUSSION

The pancreas is formed by ventral and dorsal endodermal buds. At the 6-7th week of gestation the ventral pancreas fuses with the dorsal pancreas and then both of these buds form the main pancreatic duct. During this complex development, congenital abnormalities can occur.

Complete agenesis of the pancreas and agenesis of the ventral pancreas are not compatible with life [2]. Partial agenesis of the dorsal pancreas is another anomaly which has been reported in 14 cases between 1913 and 1999 [1]. The differential diagnosis of dorsal pancreatic agenesis must be made between pancreas divisum and autodigestion due to chronic pancreatitis. The chief complaint of the patients with dorsal pancreatic agenesis is abdominal pain which is possibly related to the underdevelopment of the papillary muscle [3]. Most of them also have diabetes mellitus probably because most of the islet cells are located in the pancreatic body and tail [1]. Absence of the dorsal pancreas may co-exist together with polysplenia syndrome [4] and may also cause acute pancreatitis [5, 6] and chronic pancreatitis [3].

In the literature, there is a case of pancreatic adenocarcinoma associated with dorsal agenesis [7] and also a familial case of agenesis [8].

Two possible mechanisms may play a role in the pathogenesis of pancreatitis in these patients, namely sphincter of Oddi dysfunction [9] and hypertrophy of the remnant ventral gland with higher intrapancreatic duct pressures [10].

Distal pancreatic agenesis involves the body and tail, generally starting from the midline. The situation may be distinguished from fatty infiltration of pancreatic tissue by the presence of volume loss and intestinal loops filling the location of the presumed distal pancreas. Namely, if fatty infiltration had taken place, there would have been fatty tissue in the expected location of the distal pancreas. Further discrimination may only be possible at pathological examination which would demonstrate the presence of islet cells within the excised tissue. However, this patient was not operated on; therefore, pathological evaluation was not possible and diagnosis has to be established based on imaging findings alone.

The most common cause of chronic pancreatitis is alcohol ingestion followed by tropical, hereditary, metabolic, autoimmune

pancreatitis. There is a subclass which is defined as “anatomic” chronic pancreatitis, namely, a pancreatitis associated with obstructive pancreatitis, pancreas divisum, post-traumatic pancreatic duct scars and periampullary duodenal wall cysts [11]. Chronic pancreatitis due to dorsal pancreatic agenesis can also be defined as “anatomic” pancreatitis which probably causes an impairment of pancreatic secretion and higher intraductal pressures in the dense ventral part. Its diagnosis requires a high index of suspicion. Before the use of modern imaging techniques, the diagnosis was only made by autopsy or at surgery. Now, abdominal US, CT, ERCP, MRCP and EUS can be used for a diagnosis [12]. EUS seems to be a much more sensitive and noninvasive method in the diagnosis of pancreatic disease in comparison to other diagnostic modalities [13].

Complete agenesis of the dorsal pancreas will be able to be diagnosed much more easily with these techniques in the future [12, 14], and its association with clinical syndromes will be better understood.

Received March 9th, 2007 - Accepted May 10th, 2006

Keywords Abdominal Pain; Congenital, Hereditary, and Neonatal Diseases and Abnormalities; Pancreatitis, Chronic

Conflict of interest The authors have no potential conflicts of interest

Correspondence

Oya Uygur-Bayramiçli
Bagdat cad Bölükbasi apt No 138/10
Feneryolu, Kadıköy
Istanbul
Turkey

Phone: +90-216.541.4318

Fax: +90-216.541.4318

E-mail: oyabayramicli@yahoo.com.tr

Document URL: <http://www.joplink.net/prev/200707/08.html>

References

1. Fukuoka K, Ajiki T, Yamamoto M, Fujiwara H, Onoyama H, Fujita T, et al. Complete agenesis of the dorsal pancreas. *J Hepatobiliary Pancreat Surg* 1999; 6:94-7. [PMID 10436244]

2. Voldsgaard P, Kryger-Baggesen N, Lisse I. Agenesis of pancreas. *Acta Paediatr* 1994; 83:791-3. [PMID 7949819]

3. Klein WA, Dabezies MA, Friedman AC, Caroline DF, Boden GH, Cohen S. Agenesis of dorsal pancreas in a patient with weight loss and diabetes mellitus. *Dig Dis Sci* 1994; 39:1708-13. [PMID 8050322]

4. Sener RN, Alper H. Polysplenia syndrome: a case associated with transhepatic portal vein, short pancreas, and left inferior vena cava with hemiazygous continuation. *Abdom Imaging* 1994; 19:64-6. [PMID 8161909]

5. Guclu M, Serin E, Ulucan S, Kul K, Ozer B, Gumurdulu Y, et al. Agenesis of the dorsal pancreas in a patient with recurrent acute pancreatitis: case report and review. *Gastrointest Endosc* 2004; 60:472-5. [PMID 15332050]

6. Rakesh K, Choung OW, Reddy DN. Agenesis of the dorsal pancreas (ADP) and pancreatitis - is there an association? *Indian J Gastroenterol* 2006; 25:35-6. [PMID 16567893]

7. Uluhan S, Yakar T, Koc Z, Kayaselcuk F, Torer N. Adenocarcinoma of the pancreas associated with dorsal agenesis. *Pancreas* 2006; 33:437-9. [PMID 17079954]

8. Wildling R, Schnedl WJ, Reisinger EC, Schreiber F, Lipp RW, Lederer A, Krejs GJ. Agenesis of the dorsal pancreas in a woman with diabetes mellitus and in both of her sons. *Gastroenterology* 1993; 104:1182-6. [PMID 8462806]

9. Nishimori I, Okazaki K, Morita M, Miyao M, Sakamoto Y, Kagiya S, et al. Congenital hypoplasia of the dorsal pancreas :with special reference to duodenal papillary dysfunction. *Am J Gastroenterol* 1990; 85:1029-33. [PMID 2197855]

10. Gold RP. Agenesis and pseudo-agenesis of the dorsal pancreas. *Abdom Imaging* 1993; 18:141-4. [PMID 8439753]

11. Wenig BM, Heffes CS. Inflammatory, infectious and other nonneoplastic disorders of the pancreas. In: Odze RD, Goldblum JR, Crawford JM, eds. *Surgical Pathology of the GI Tract, Liver, Biliary Tract and Pancreas*. Philadelphia, Saunders, 2004:673-97.

12. Sempere L, Aparicio JR, Martinez J, Casellas JA, de Madaria E, Perez-Mateo M. Role of endoscopic ultrasound in the diagnosis of agenesis of the dorsal pancreas. *JOP. J Pancreas (Online)* 2006; 7:411-6. [PMID 16832139]

13. Sahai AV. EUS and chronic pancreatitis. *Gastrointest Endosc* 2002; 56:S76-81. [PMID 12297754]

14. Karcaaltincaba M. CT differentiation of distal pancreas fat replacement and distal pancreas agenesis. *Surg Radiol Anat* 2006; 28:637-41. [PMID 17033736]