

## CASE REPORT

# Pancreas Sparing Resection for Giant Hamartoma of Brunner's Glands

Vikas Gupta<sup>1</sup>, Virendra Singh<sup>2</sup>, Naveen Kalra<sup>3</sup>, Kim Vaiphei<sup>4</sup>

Departments of <sup>1</sup>General Surgery, <sup>2</sup>Hepatology, <sup>3</sup>Radiodiagnosis, <sup>4</sup>Histopathology, Postgraduate Institute of Medical Education and Research. Chandigarh, India

### ABSTRACT

**Context** Benign proliferative changes of the Brunner's glands account for about 10% of neoplasias of the duodenal bulb. **Case report** The authors present a case of giant hamartoma of Brunner's glands. The patient presented clinically with vague epigastric discomfort. A pancreas-sparing duodenal resection was performed. The patient made an uneventful recovery and is well at a one year follow-up. The diagnosis was established on histopathology. **Conclusion** Duodenal hamartomas are rare and may become very large, mandating surgical removal. A pancreas-sparing duodenal resection is one of the modalities of treating such lesions.

### INTRODUCTION

Brunner's glands are mucus secreting acinar glands situated in the deep mucosa and submucosa of the duodenum which empty into the crypts of Lieberkühn [1]. Brunner's gland hyperplasia in the duodenum is a rare, benign, hamartomatous, proliferative disorder of the duodenum and accounts for about 10% of neoplasias of the duodenal bulb [1, 2]. It is characterized by the proliferation of the acinar glands [1, 2, 3]. Owing to its rarity, these lesions can be mistaken for malignancy on radiological and endoscopic examination s [2, 4, 5, 6]. Small masses can present with bleeding, intussusceptions and are rarely asymptomatic [2, 7, 8]. Large masses may cause obstructive and compressive symptoms which may depend upon the location of the tumour [4, 5, 9]. These lesions sometimes become enormous and are called giant brunneromas [4, 5, 9]. A variety of endoscopic and surgical approaches have been described to tackle these lesions based on their size and location [4, 5, 8, 9]. The present report describes successful surgical management of a large lesion by an organ-sparing procedure.

### CASE REPORT

#### Clinical Presentation

A 28-year-old woman presented with pain in the upper abdomen and occasional vomiting of 3 months duration. General physical, systemic and abdominal examinations were normal. Her biochemical, hematological and coagulation parameters were normal. She underwent an esophagogastroduodenoscopy, which revealed an extramucosal mass lesion in the gastric antrum, and the first and second parts of the duodenum, displacing the lumen eccentrically. Duodenal biopsy showed non specific inflammation.

#### Imaging

A contrast-enhanced computerized tomogram of the abdomen revealed an exophytic mass arising from the medial wall of the first and second parts of the duodenum displacing the pancreas medially. However, the fat plane between the mass and the pancreas was preserved (Figure 1).

#### Operative Findings and Technique

Initial exploration was performed by a bilateral subcostal incision. A generous Kocher's maneuver was performed to facilitate the examination. There was a 8x10 cm exophytic mass arising from the antrum of the stomach and medial wall of the duodenum (1<sup>st</sup> and 2<sup>nd</sup> parts) extending beyond the papilla (Figure 2). The tumour could easily be separated from the pancreas. Therefore, the decision to perform a pancreas-sparing resection was taken. The gastric antrum was divided as is done in a classical pancreaticoduodenectomy. The proximal jejunum was transected about 15 cm distal to the ligament of Treitz. The jejunum and the duodenum

Received January 4<sup>th</sup>, 2009 - Accepted January 12<sup>th</sup>, 2009

**Key words** Brunner Glands; Duodenal Neoplasms; Hamartoma; Hyperplasia; Pancreas; Polyps

**Correspondence** Vikas Gupta

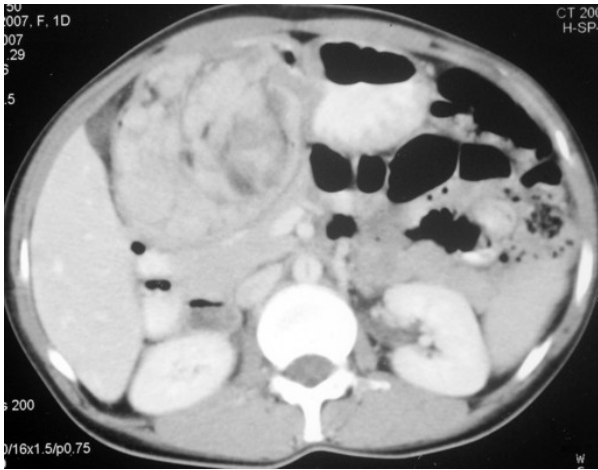Department of General Surgery, Gastrointestinal Surgery Unit, Postgraduate Institute of Medical Education and Research, Chandigarh 160012, India

Phone: +91-172.275.6645; Fax: 91-172-274.4401;

Mobile: +91-987.204.1120; +91-991.420.9645

E-mail: vikaspgi@gmail.com

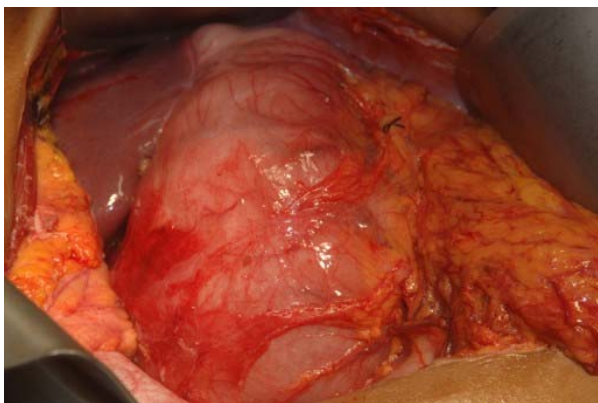
**Document URL** <http://www.joplink.net/prev/200903/12.html>



**Figure 1.** Axial CECT section shows a large heterogeneous mass lesion in relation to the antropyloric region of the stomach and the C loop of the duodenum. Fat plane with the head of the pancreas is preserved.

were separated from the uncinate process as is done in a standard pancreaticoduodenectomy. Cholecystectomy was performed in a retrograde fashion and a catheter was introduced through the cystic duct stump to identify the papilla. The dissection was continued in the interface between the pancreas and the duodenum by ligating and dividing all the vessels. Upon reaching the major papilla, the duodenum was made taut and the papilla was divided. During the course of the dissection, the minor papilla was ligated.

Sphincteroplasty and septotomy were performed to achieve a wide anastomosis with the jejunum as has previously been described by Sarmiento *et al.* [10]. The end of the jejunum was stapled. Along the antimesenteric border of the jejunum, the major papilla was anastomosed in a mucosa to mucosa fashion using a fine absorbable suture. The knots of the posterior layer were placed inside while those of the anterior layer were placed outside. The seromuscular layer of the jejunum was sutured to the pancreatic substance with a non-absorbable suture. A 6 Fr external stent was placed in the pancreatic duct and an 8 Fr external stent was placed in the common bile duct. Enteric



**Figure 2.** Operative image showing a large tumour mass occupying the distal antrum, and the first and second parts of the duodenum.

anastomosis was performed 15 cm downstream from the papillary anastomosis.

She made an uneventful recovery and is well at a one year follow-up.

### Pathology

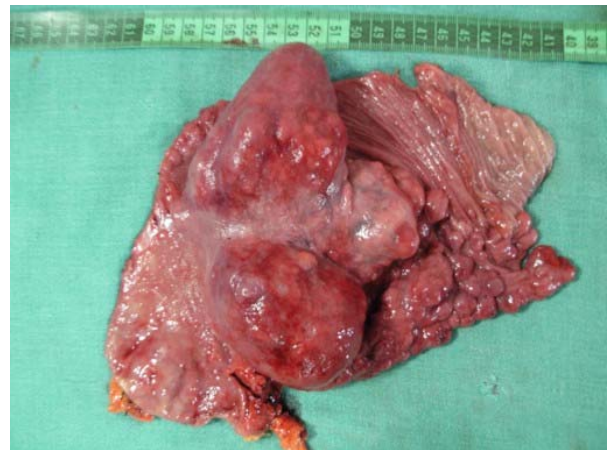The gross specimen revealed a large polypoidal mass occupying most of the resected specimen (Figure 3). Histopathology of the specimen from the polypoidal lesion showed collections of Brunner's glands in the submucosa. The Brunner's glands showed a lobular pattern of arrangement and each lobule appeared to have a separate draining duct. Strands of fibrous tissue and smooth muscles were also seen between the lobules (Figure 4).

### DISCUSSION

Benign tumors of the duodenum are very rare. In a large series of more than 215,000 autopsies, only 0.008% was benign duodenal tumours and those arising from Brunner's glands accounted for 11% of these benign lesions [3]. The term Brunner's gland hyperplasia has been used interchangeably with Brunner's gland hamartoma, Brunner's gland adenoma and brunneroma. The latter term is a misnomer as the lesion does not contain any neoplastic element but it is, in fact, a hamartoma [1, 2, 3, 4, 5, 11, 12]. The exact incidence of the condition is difficult to determine because of the heterogeneity of nomenclature. In an analysis of 2,800 duodenal specimens, Feyrter [13] classified Brunner's gland hyperplasia into three types based on the gross morphological features. However, the various types could represent the different stages of evolution of the same lesion.

The exact pathogenesis of these lesions is not well known but is thought to be more often associated with *Helicobacter pylori* infections and chronic pancreatitis [11, 14]. The present case did not have any of these underlying risk factors.

The most common location of these lesions is the posterior wall of the first and second parts of the duodenum. In a study of 27 patients, Levine *et al.* [15]



**Figure 3.** Gross specimen large and small multiple intraluminal polypoidal lobulated masses occupying the duodenum.

found 70% of the lesions located in the duodenal bulb and 26% to be located in the second part of the duodenum. However, the occurrence of these lesions as far as the distal ileum has also been described [16]. The present case is peculiar as to the extent of involvement which started from the gastric antrum and extended into the duodenum beyond the papilla.

Despite their rare occurrence, these lesions tend to be clinically significant as 45% of them bleed and 51% cause enteric obstruction [17]. However, with the advent of endoscopy and barium examination of the gastrointestinal tract, asymptomatic small lesions are detected more often. Occasionally, these lesions are a rare cause of gastric outlet [18], duodenal [19] or small bowel obstruction [16, 20] or upper gastrointestinal hemorrhage [21], and require excision. Concomitant biliary and pancreatic obstruction and consequent pancreatitis caused by these lesions has been described [12, 22]. The occurrence of surgical jaundice due to the mass lesion produced by the tumour in the periampullary location has been described [4]. For the most part, these lesions are benign but the coexistence of malignancy has also been described. In an analysis of more than seven hundred cases with Brunner's gland hyperplasia, Sakuri *et al.* [2] reported coexisting dysplasia, and invasive carcinoma in only 2% cases.

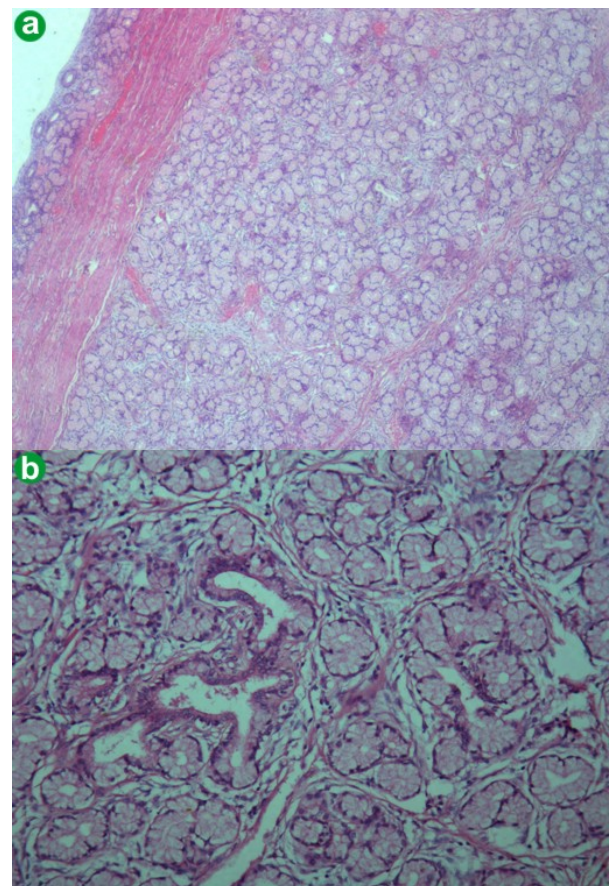
All symptomatic lesions should be treated. Small lesions are amenable to endoscopic removal. Various strategies such as snare polypectomy, submucosal resections and hemoclip application have been described depending on the individual situation [9, 11, 17, 21, 23, 24]. Large lesions require removal as it is difficult to rule out malignancy in the majority of cases. Moreover, proven cases of malignancy developing in Brunner's hyperplasia have also been described [2]. Coriat *et al.* [9] reported the endoscopic removal of a large lesion. Others have also reported endoscopic polypectomy removal of a large lesion. Obha *et al.* [25] described a modified endoscopic submucosal dissection technique to remove a large Brunner's gland hyperplasia.

Laparoscopic removal of small and large lesions has been described [8, 26]. Iusco *et al.* [5] resorted to radical resection in a large Brunner's gland hamartoma where it was difficult to rule out malignancy. Hol *et al.* [4] performed a pancreaticoduodenectomy for a periampullary giant lesion with a suspicion of coexisting malignancy. The present report is the first of its kind where a pancreas-sparing resection has been performed for a large brunneroma. Owing to the voluminous size of the lesion and uncertainty in the diagnosis, resectional treatment was mandated.

Since the first description in 1984, pancreas-sparing duodenal resection has been widely used for various benign and malignant conditions of the duodenum [26, 27]. These include familial adenomatous polyposis, trauma, lymphoma, leiomyosarcoma, corrosive injury and duodenal bleeding [10, 27, 28, 29, 30, 31, 32]. The proposed potential advantages are the restoration of near normal continuity of the gastrointestinal tract, and

organ preservation leads to a better long-term outcome. In a series of 21 pancreas-sparing resections, Mackey *et al.* [28] found it to be a safe method for treating patients with Spigelman's stage IV duodenal polyposis. Sarmiento *et al.* [10] described a good absorptive capacity, weight gain and quality of life in patients with duodenal polyposis undergoing a pancreas-sparing resection. Suzuki *et al.* [29] performed pancreas sparing resection of the third and fourth portions of the duodenum in a patient with a large leiomyosarcoma. Absence of the contiguous involvement of the pancreas and lymph nodal metastasis were the factors dictating this type of resection [10, 27, 28, 29].

Once the resection is performed, the reconstruction can be tailored according to the anatomy and involvement of the pancreaticobiliary complex. The choice lies between transplanting the duodenal button including the papilla into the jejunum or excising the major papilla and forming a neo-pancreaticobiliary junction [10, 27, 28, 29, 30, 31, 32]. The former technique is simple to perform but carries the risk of leaving behind the diseased duodenal mucosa. The latter is more technically demanding [10, 27, 28, 29, 30, 31, 32]. In the present case, a neopancreaticobiliary junction was created which was anastomosed to the jejunum.



**Figure 4.** a. Low power photomicrograph to show stretched-out duodenal mucosa overlying the mass lesion (H&E, x60). b. High power photomicrograph to show lobular collection of normal looking mucous glands with a draining intralobular duct (H&E, x240).

In conclusion, a duodenal hamartoma is a rare disorder in which the hamartoma may become very large, mandating surgical removal. A pancreas-sparing duodenal resection is one of the modalities of treating such lesions.

---

**Conflict of interest** The authors have no potential conflicts of interest

---

#### References

1. O'Riordan BG, Vilor M, Herrera L. Small bowel tumors: an overview. *Dig Dis* 1996; 14:245-57. [PMID 8843980]
2. Sakurai T, Sakashita H, Honjo G, Kasyu I, Manabe T. Gastric foveolar metaplasia with dysplastic changes in Brunner gland hyperplasia: possible precursor lesions for Brunner gland adenocarcinoma. *Am J Surg Pathol* 2005; 29:1442-8. [PMID 16224210]
3. Botsford W, Crowe P, Crocker DW. Tumors of the small intestine. A review of experience with 115 cases including a report of a rare case of malignant hemangio-endothelioma. *Am J Surg* 1962; 103:358-365. [PMID 13871677]
4. Hol JW, Stuijbergen WN, Teepeen JL, van Laarhoven CJ. Giant Brunner's hamartomas of the duodenum and obstructive jaundice. An overview of the literature and suspicion of malignancy in a case. *Dig Surg* 2007; 24:452-5. [PMID 18025786]
5. Iusco D, Roncoroni L, Violi V, Donadei E, Sarli L. Brunner's gland hamartoma: 'over-treatment' of a voluminous mass simulating a malignancy of the pancreatic-duodenal area. *JOP. J Pancreas (Online)* 2005; 6:348-53. [PMID 16006686]
6. Brookes MJ, Manjunatha S, Allen CA, Cox M. Malignant potential in a Brunner's gland hamartoma. *Postgrad Med J* 2003; 79:416-417. [PMID 12897224]
7. Patel ND, Levy AD, Mehrotra AK, Sobin LH. Brunner's gland hyperplasia and hamartoma: imaging features with clinicopathologic correlation. *AJR Am J Roentgenol* 2006; 187:715-22. [PMID 16928936]
8. Baladas HG, Borody TJ, Smith GS, Dempsey MB, Richardson MA, Falk GL. Laparoscopic excision of a Brunner's gland hamartoma of the duodenum. *Surg Endosc* 2002; 16:1636. [PMID 12196895]
9. Coriat R, Mozer-Bernardeau M, Terris B, Chryssostalis A, Prat F, Chaussade S. Endoscopic resection of a large Brunner's gland hamartoma. *Gastroenterol Clin Biol* 2008; 32:11-4. [PMID 18341972]
10. Sarmiento JM, Thompson GB, Nagorney DM, Donohue JH, Farnell MB. Pancreas-sparing duodenectomy for duodenal polyposis. *Arch Surg* 2002; 137:557-63. [PMID 11982469]
11. Kovacević I, Ljubčić N, Cupić H, Doko M, Zovak M, Troskot B, et al. Helicobacter pylori infection in patients with Brunner's gland adenoma. *Acta Med Croatica* 2001; 55:157-60. [PMID 12398018]
12. Mayoral W, Salcedo JA, Montgomery E, Al-Kawas FH. Biliary obstruction and pancreatitis caused by Brunner's gland hyperplasia of the ampulla of Vater: a case report and review of the literature. *Endoscopy* 2000; 32:998-1001. [PMID 11147953]
13. Feyrter F. Ueber wucherung der Brunnerschen Drusen. *Virchows Arch* 1938; 293:509-26.
14. Kurella RR, Ancha HR, Hussain S, Lightfoot SA, Harty R. Evolution of Brunner gland hamartoma associated with Helicobacter pylori infection. *South Med J* 2008; 101:648-50. [PMID 18475238]
15. Levine JA, Burgart LJ, Batts KP, Wang KK. Brunner's gland hamartomas: clinical presentation and pathological features of 27 cases. *Am J Gastroenterol* 1995; 90:290-4. [PMID 7847303]
16. Henken EM, Forouhar F. Hamartoma of Brunner's gland causing partial obstruction of the ileum. *J Can Assoc Radiol* 1983; 34:73-4. [PMID 6841428]
17. Walden DT, Marcon NE. Endoscopic injection and polypectomy for bleeding Brunner's gland hamartoma: case report and expanded literature review. *Gastrointest Endosc* 1998; 47:403-7. [PMID 9609436]
18. Lingawi SS, Filipenko JD. Brunner's gland hamartoma causing gastric outlet obstructive symptoms. *South Med J* 1998; 91:964-5. [PMID 9786295]
19. Mumtaz R, Shah IA, Ramirez FC. Brunner's gland hamartoma simulating a pancreatic mass with duodenal obstruction. *Gastrointest Endosc* 2002; 56:932-934. [PMID 12447318]
20. Tomikashi K, Fukuda M, Nakano K, Takami S, Imamura M, Nakajima T. Gastrointestinal obstruction caused by the spontaneously detached Brunner's gland hamartoma of the duodenum. *J Gastroenterol Hepatol* 2006; 21:1502-5. [PMID 16911706]
21. de Nes LC, Ouwehand F, Peters SH, Boom MJ. A large Brunner's gland hamartoma causing gastrointestinal bleeding and obstruction. *Dig Surg* 2007; 24:450-2. [PMID 18025785]
22. Stermer E, Elias N, Keren D, Rainis T, Goldstein O, Lavy A. Acute pancreatitis and upper gastrointestinal bleeding as presenting symptoms of duodenal Brunner's gland hamartoma. *Can J Gastroenterol* 2006; 20:541-2. [PMID 16955152]
23. Chen YY, Su WW, Soon MS, Yen HH. Hemoclip-assisted polypectomy of large duodenal Brunner's gland hamartoma. *Dig Dis Sci* 2006; 51:1670-2. [PMID 16927147]
24. Tai M, Yoshikawa I, Kume K, Murata I, Otsuki M. A large Brunner's gland hamartoma resected by endoscopic polypectomy. *Gastrointest Endosc* 2001; 53:207-8. [PMID 11174294]
25. Ohba R, Otaka M, Jin M, Odashima M, Matsuhashi T, Horikawa Y, et al. Large Brunner's gland hyperplasia treated with modified endoscopic submucosal dissection. *Dig Dis Sci* 2007; 52:170-2. [PMID 17171443]
26. Adell-Carceller R, Salvador-Sanchis JL, Navarro-Navarro J, Segarra-Soria M, Garcia-Calvo R, Gibert-Gerez J, Colom-Costa J. Laparoscopically treated duodenal hamartoma of Brunner's glands. *Surg Laparosc Endosc* 1997; 7:298-300. [PMID 9282760]
27. Nagai H, Hyodo M, Kurihara K, Ohki J, Yasuda T, Kasahara K, et al. Pancreas-sparing duodenectomy: classification, indication and procedures. *Hepatogastroenterology* 1999; 46:1953-8. [PMID 10430376]
28. Mackey R, Walsh RM, Chung R, Brown N, Smith A, Church J, Burke C. Pancreas-sparing duodenectomy is effective management for familial adenomatous polyposis. *J Gastrointest Surg* 2005; 9:1088-93. [PMID 16269379]
29. Suzuki H, Yasui A. Pancreas-sparing duodenectomy for a huge leiomyosarcoma in the third portion of the duodenum. *J Hepatobiliary Pancreat Surg* 1999; 6:414-7. [PMID 10664293]
30. Chung RS, Church JM, vanStolk R. Pancreas-sparing duodenectomy: indications, surgical technique, and results. *Surgery* 1995; 117:254-9. [PMID 7878529]
31. Eisenberger CF, Knoefel WT, Peiper M, Yekebas EF, Hosch SB, Busch C, Izbicki JR. Pancreas-sparing duodenectomy in duodenal pathology: indications and results. *Hepatogastroenterology* 2004; 51:727-31. [PMID 15143902]
32. Lundell L, Hyltander A, Liedman B. Pancreas-sparing duodenectomy: technique and indications. *Eur J Surg* 2002; 168:74-7. [PMID 12113274]