

# Role of Repeat Computerized Tomography in the Selective Non-Operative Management of Splenic Trauma

Ferguson R<sup>1\*</sup>, Lin J<sup>1</sup>, Tunzi M<sup>1</sup>, Donn E<sup>1</sup> and McCague A<sup>2</sup>

<sup>1</sup>Touro University College of Osteopathic Medicine, Vallejo, CA, USA

<sup>2</sup>Department of Surgery, Natividad Medical Center, Salinas, CA, USA

\*Corresponding author: Ferguson R, Touro University College of Osteopathic Medicine, Vallejo, CA, USA, E-mail: fergusonjryan@gmail.com

Received date: July 03, 2020; Accepted date: July 17, 2020; Published date: July 24, 2020

Citation: Ferguson R, Lin J, Tunzi M, Donn E, McCague A (2020) Role of Repeat Computerized Tomography in the Selective Non-operative Management of Splenic Trauma. Trauma Acute Care Vol.5 No.2: 80. DOI: 10.36648/2476-2105.5.2.80

Copyright: ©2020 Ferguson R, et al. This is an open-access article distributed under the terms of the Creative Commons Attribution License, which permits unrestricted use, distribution, and reproduction in any medium, provided the original author and source are credited.

## Abstract

Splenic injuries are some of the most common injuries accompanying blunt abdominal trauma. Non-operative management (NOM) of these injuries is a standard of care for hemodynamically stable patients. Computed Tomography (CT) imaging is helpful in evaluating solid organ trauma and determining treatment options; however, indications for follow up CT scans are unclear. Current guidelines at our Level II Trauma Center recommend that a repeat CT scan should be performed for patients undergoing NOM of splenic injuries Grade III and above at 48 hours from admission-including those that undergo embolization. This 2-year retrospective study assessed the role of repeat CT scans in NOM by analyzing the indications for surgery in NOM failures. NOM was undertaken in 35 patients with splenic trauma of Grade III or higher. Scans were repeated in 28 (80%) patients with a median time of 65.68 hours. There was failure of NOM (NOMF) in 4 patients. All patients had clinical deterioration along with follow-up imaging prior to delayed surgery. The data suggests that repeat CT scans have a limited role in NOM of splenic trauma. Although this study is limited by our small sample size, we propose that instead of mandatory repeat CT scans, clinical judgment should be exercised to avoid unnecessary radiation exposure in clinically stable patients. This study prompts further questions concerning the role of repeat computerized tomography in blunt splenic trauma and illustrates the need for a larger multicenter trial to address this question as well.

**Keywords:** Abdominal trauma; Trauma; CT scan; Blunt splenic trauma

## Introduction

Spleen injuries are graded on a scale of I through V based on the American Association for the Surgery of Trauma (AAST) spleen injury scale [1]. A higher grade indicates a more severe injury. Grading is done by a radiologist after reviewing abdominal computed tomography (CT) scans with intravenous (IV) contrast looking for lacerations, hematomas, extravasation of contrast or pseudoaneurysms. Management of splenic injury is largely dependent on the grade of injury seen on CT imaging in addition to the patient's clinical appearance.

Recent improvements in computerized tomography has allowed for selective non-operative management (NOM) of blunt splenic injuries in hemodynamically stable patients to become the new standard in care. It has widely been accepted as a well-tolerated approach in both pediatric and adult populations [2]. Some key points of NOM such as the need and timing of repeat CT scans are less clearly defined. Previous studies done by Sharma et al. [3]. And Shapiro et al. [4]. Found that repeated CT scans did not change patient management in the majority of cases. In contrast, Weinberg et al. [5]. Showed that repeated CT imaging at 24 hours to 48 hours in Grade II and higher splenic injuries identifies latent pseudoaneurysms that then undergo angioembolization with improved outcome.

Current guidelines at our Level II Trauma Center recommend that a repeat CT scan should be performed for patients with Grade III and above splenic injuries managed non-operatively at 48 hours from admission (**Figure 1**) [6].

Management of Blunt Splenic Injuries

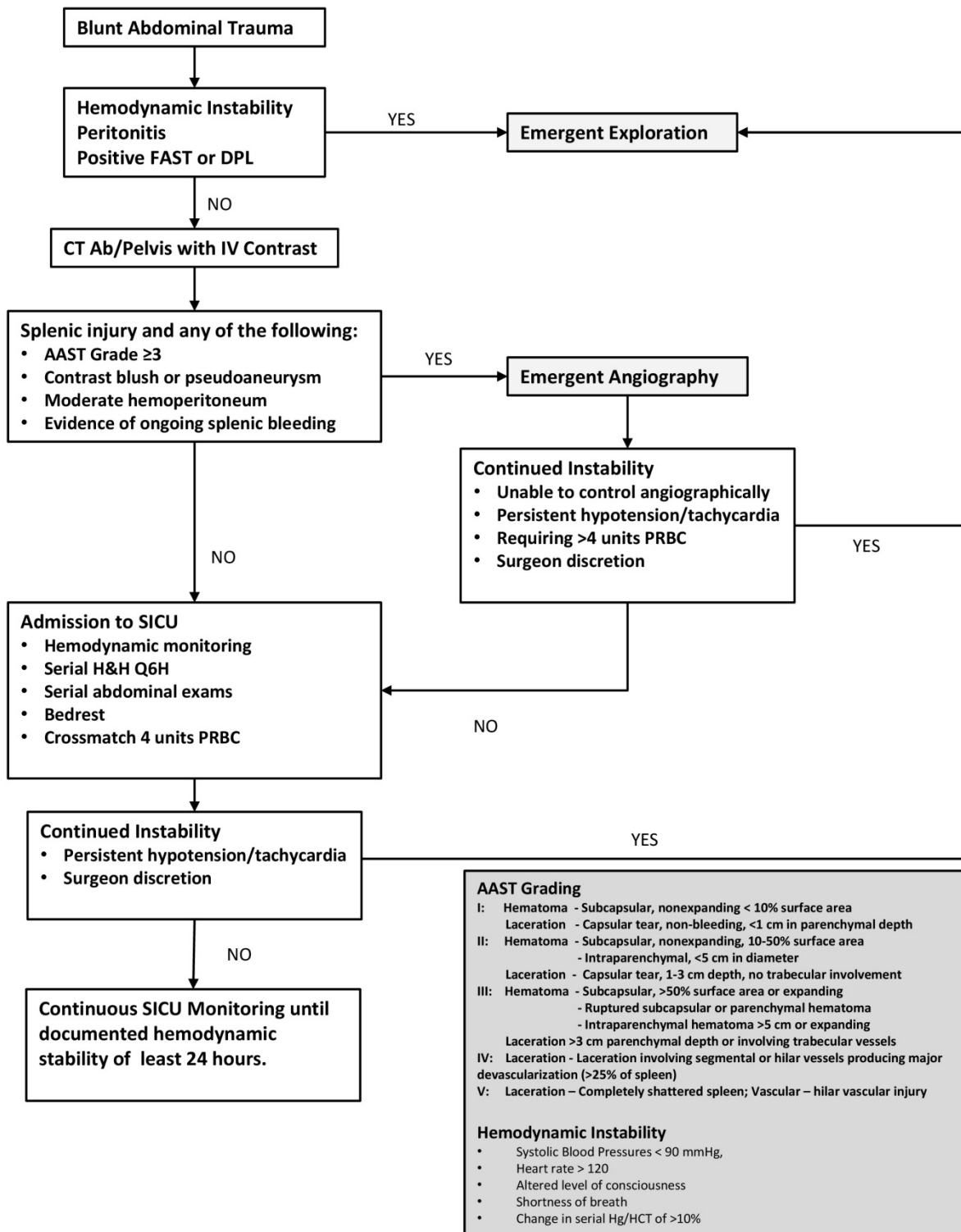


Figure 1: Management of blunt splenic injuries.

The logic is to identify delayed hemorrhagic complications in the patient undergoing non-operative management of blunt

splenic trauma. Such complications include splenic pseudoaneurysm formation, delayed bleed and spleen capsule

rupture. However, there is limited data to determine the necessity of repeated imaging regardless of clinical findings. This uncertainty pertains to when follow up CT scans should be performed, if at all.

In a time when we are continually aware of the radiation risks that CT scans have, it has become increasingly important to be judicious with CT imaging. The risks and benefits must be assessed in order to provide the highest quality and safest level of care possible for patients. This study's goal was to review our facility's recommended policy of follow up CT scans and evaluate the outcomes associated with this practice. Results from the study were to inform the trauma service leadership regarding the effectiveness of this policy in addition to providing a comprehensive review of the hospital's management of blunt splenic injury [7]. The prediction is that using sound clinical judgment to determine if and when a repeat CT scan should be performed is a better strategy than getting a mandatory scan for every patient with a Grade III laceration.

## Methods

This project received an exemption status from the Institutional Review Board of Touro University of California-College of Osteopathic Medicine. It was classified as exempt for its retrospective analysis of anonymous data without any patient identifiable information. The database was created in Microsoft Excel (Microsoft Excel; Microsoft Corporation, Redmond, WA) and consists of all patients with a documented splenic injury who arrived to our facility from January 2015 to January 2017. Natividad Medical Center is a 172 bed county hospital and level II trauma center. It has been providing care in Monterey County, California for 132 years and its trauma program was established in January 2015. It is the only trauma center within the county.

The variables in the database included the following: splenic injury grade, baseline vital signs, timing of CT scans,

complications during hospital stay, deep vein thrombosis prophylaxis, procedures performed, hospital length of stay, Intensive Care Unit (ICU) length of stay and discharge disposition. A total of 105 cases with documented splenic injury were evaluated from the entire trauma registry over the 2 year period.

Descriptive statistics for each outcome pertaining to each grade was obtained. In depth review of the cases that failed NOM was performed. The goal was to compare these failures and observe for patterns in clinical presentation.

## Results

Blunt splenic trauma was seen in 105 patients [8]. One patient with severe multiple injuries died soon after arrival in the operating room during emergent laparotomy. After excluding one immediate death, 104 patients were assessed. Of these 104 patients, 49 had Grade III and above splenic injuries and were selected to evaluate current guidelines at our facility. Operative management was done in 14. This study pertains to the remaining 35 treated non-operatively.

Non-operative management failed in 4 patients. Repeat CT scan was done prior to surgery and all 4 had deterioration of CT abnormalities. These patients also had increased abdominal pain with clinical signs of peritonitis. Out of the 35 patients treated non-operatively, 28 received repeat CT scans. Of these 28 patients, repeat CT scans were unchanged or improved in 21 patients and showed deterioration in 7. As illustrated above, 4 patients with deterioration on repeat CT failed non-operative management. The other 3 (74, 158, 141) had repeat CT scans that revealed pseudoaneurysms or delayed bleeds which were managed with splenic artery embolization or observation. These 3 patients also presented with increasing abdominal pain and/or decreased hemoglobin and hematocrit. Results are presented in **Table 1**.

**Table 1:** Role of CT in patients with failure of non-operative management.

Case No	Age, Sex	Initial CT Grade	Time Delayed Clinical Assessment	Repeat CT Prior to Delayed Surgery	Surgery
1	37M	Grade 4	D2: HR↑, Decrease Hb (9.8→7.9)	CT Worse: Spleen=increase fluid	Distal pancreatomy, splenectomy
2	66M	Grade 4	D9: Pain↑, Rigidity↑	CT Worse: Spleen=SBO	Right hemicolectomy, Splenectomy
3	31F	Grade 5	D24: HR↑, Pain↑, Shortness of Breath↑	CT Worse: Enlarged perisplenic hematoma, Left sided pleural effusion	VATS, Splenic cystectomy partial splenectomy,
4	44M	Normal Spleen	D9: HR↑, Pain↑, Decrease Hb (14.4→9.9)	CT Worse: Grade 3 laceration with delayed splenic rupture	Splenectomy, Drainage of pancreatic abscess

D(day), HR↑ (>120 bpm), Spleen=(unchanged)

## Discussion

Initial CT scans were done in 35 NOM patients; repeat CT scans were done in 28 patients. 7 of these 28 patients showed worse findings on follow up CT scan. Of those who had worse repeat CT scans, 4 of 7 needed surgery because of clinical deterioration. All 4 patients had signs of hemodynamic

instability or clinical signs of peritonitis. CT scan in the other 3 patients showed signs of splenic pseudoaneurysm or delayed splenic rupture. 2 of these patients received interventional radiology guided embolization of the splenic artery while the third patient refused treatment. All three patients had decreasing hemoglobin and hematocrit. The remaining 21 out of 28 patients had repeat CT scans despite hemodynamic stability

and stable hemoglobin and hematocrit levels. Follow up scans of these patients revealed unchanged or improved findings.

There appears to be a limited role of follow-up imaging in NOM of clinically stable patients. Repeat CT scans should be done more selectively and guided by a patient's clinical status. However, a follow up CT scan is still an important tool to evaluate for potential delayed bleeds in patients who have a normal initial abdominal CT scan. One patient in our study presented to the emergency department with abdominal pain after being assaulted; initial CT of the abdomen was normal and the patient was discharged. Repeat CT scan done 9 days after arrival to evaluate for persistent abdominal pain and unexplained drop in hemoglobin revealed an undiagnosed grade III splenic injury with moderate hemoperitoneum. The patient was subsequently taken to the operating room and treated successfully [9].

There were several key limitations with this study. Given the study's small sample size, this power of the study is inadequate to make any overarching definite conclusions about all patients who sustain grade III and above splenic injuries. Moreover given the small number of pseudoaneurysms detected and reviewed in this study, it is difficult to make generalized conclusions about the entire population regarding pseudoaneurysm management. Future investigation is needed at a later time as more spleen injuries are added to the database at this institution. This is the benefit of having a trauma registry that is continually updated. Periodic review of the practices and outcomes can provide insight into key areas where improvement is needed.

## Conclusion

In this 2-year retrospective study we assessed the role of repeat CT scans in NOM by analyzing the indications for surgery in NOM failures. The data suggests that repeat CT scans have a limited role in NOM of splenic trauma. Although this study is limited by our small sample size, we propose that instead of mandatory repeat CT scans, clinical judgment should be exercised to avoid unnecessary radiation exposure in clinically stable patients. Repeat CT scans should be done more selectively and guided by a patient's clinical status. This study prompts further questions concerning the role of repeat computerized tomography in blunt splenic trauma and illustrates

the need for a larger multicenter trial to address this question as well.

## Conflict of Interest

None of the authors of this manuscript have conflicts of interests or disclosures.

## Funding

There is no funding support.

## References

1. Moore EE, Cogbill TH, Jurkovich GJ, Shackford SR, Malangoni MA, et al. (1995) Organ injury scaling: Spleen and liver (1994 Revision). *J Trauma Acute Care Surg* 38: 323-324.
2. Stassen NA, Bhullar I, Cheng JD, Crandall ML, Friese RS, et al. (2012) Selective non-operative management of blunt splenic injury: An Eastern Association for the Surgery of Trauma practice management guideline. *J Trauma Acute Care Surg* 7: S294-300.
3. Sharma OP, Oswanski MF, Singer D (2005) Role of repeat computerized tomography in non-operative management of solid organ trauma. *Am Surg* 71: 244-249.
4. Shapiro MJ, Krausz C, Durham RM (1999) Overuse of splenic scoring and computed tomographic scans. *J Trauma*. 47: 651-658.
5. Weinberg JA, Manotti LJ, Croce MA, Edwards NM, Fabian TC (2007) The utility of serial computed tomography of blunt splenic injury: still worth a second look? *J Trauma* 62: 1143-1148.
6. McCray VW, Davis JW, Lemaster D, Parks SN (2008) Observation For non-operative Management of the Spleen: How long is long enough? *J Trauma* 65: 1354-1358.
7. Cocanour CS (2010) Blunt splenic injury. *Current Opinion in Critical Care* 16: 575-581.
8. Leeper WR, Leeper TJ, Ouellette D, Moffat B, Sivakumaran T, et al. (2014) Delayed hemorrhagic complications in the non-operative management of blunt splenic trauma: Early screening leads to a decrease in failure rate. *J Trauma Acute Care Surg* 76: 1349-53.
9. Lyass S, Sela T, Lebensart PD, Muggia-Sullam M (2001). Follow-up imaging studies of blunt splenic injury: do they influence management? *Isr Med Assoc J* 2001: 731-733.